



Sriwijaya Journal of Ophthalmology

Journal Homepage: <https://sriwijayaophthalmology.com/index.php/sjo>

Fortified Fluconazole Eyedrops for Treatment of *Curvularia* Corneal Ulcer

Muhammad Reza Arlas^{1*}, Petty Purwanita¹

¹Department of Ophthalmology, Faculty of Medicine, Universitas Sriwijaya, Palembang, Indonesia

ARTICLE INFO

Keywords:

Fortified fluconazole
Fluconazole eyedrops
Curvularia sp keratitis

Corresponding author:

Muhammad Reza Arlas

E-mail address:

arlas_rz@yahoo.co.id

All authors have reviewed and approved the final version of the manuscript.

<https://doi.org/10.37275/sjo.v3i2.45>

ABSTRACT

Introduction: Fungal keratitis is less common than bacterial keratitis, generally representing less than 5%–10% of corneal infections in reported clinical series in the United States. But in developing countries (Ghana, India, China) it accounts for more than 90% of the cases. Corneal trauma by plant or vegetative material is the leading risk factor for fungal keratitis. One or more topical antifungals are usually administered with systemic support of oral antifungals. The most common classes of antifungal used for medical therapy include the polyenes, azoles, and the echinocandins. **Case presentation:** A 47-year-old male presented with a widening white patch on his left eye since 4 days before coming to our hospital. The left eye was injured by wood flakes 3 weeks ago. He felt a sore, red, watery left eye and blurred vision. He washed his eyes with betel leaf water. His left eye visual acuity was 1/60 and not improved with pinhole. There were blepharospasm, ciliary and conjunctival injection. Corneal examination showed a cloudy cornea, a central corneal defect sized 8x6 mm with an irregular margin, 2/3 to stromal depth, infiltrate, satellite lesion, and positive fluorescein staining at the defect margin. KOH examination demonstrated hyphae. The culture test of left corneal discharge identified a fungi species (*Curvularia* sp). We prescribed fortified fluconazole eye drops in combination with supportive therapy for 2.5 months. This regimen showed a significant increase in visual acuity to 6/30 with pinhole improvement of 6/21 in the left eye. **Discussion:** Imidazole acts by inhibiting ergosterol biosynthesis of the fungal cell wall, through action on the cytochrome P450-dependent enzyme. This leads to cell membrane destabilization and leakage. *Curvularia* sp belongs to the family of dematiaceous fungi. Its clinical manifestations include raised lesions and feathery edges; hypopyon rarely occurs, and the prognosis is quite good. Fluconazole (2 mg/ml) is available for injection and is a well-tolerated eye drop. The intravenous injection can be used as a topical treatment and can be given subconjunctivally at the same concentration. **Conclusions:** Fortified fluconazole eyedrops (2 mg/ml) can become an alternative and additional therapy for deep fungal keratitis, especially for *Curvularia* sp.

1. Introduction

Fungal keratitis is less common than bacterial keratitis, representing less than 5% -10% of corneal infections in clinical reports reported in the United States.¹ But in developing countries (Ghana, India, China) it accounts for more than 90%.²

In corneal ulcers, some of the causes including bacteria, viruses, fungi, protozoa, and autoimmune diseases. The most common etiology of corneal ulcers is bacterial infection in the majority of cases.³⁻⁵ Fungal corneal ulcers is more common in young male outdoor workers. It is also more common in developing countries and its incidence varies widely

with climate. In the UK a study found the incidence of mycotic keratitis to be 0.32 cases per million person/year. However, in tropical and subtropical environments fungal keratitis can account for up to 50% of all infectious keratitis cases.⁴

Corneal trauma by plants or vegetative material is a major risk factor for fungal keratitis.¹ One or more topical antifungals are usually administered with oral antifungal systemic support. The classes of antifungals most commonly used for medical therapy include polyenes, azoles, and echinocandins.⁶

Corneal ulcer management aims to eradicate the

cause of the corneal ulcer, suppress the inflammatory reaction so that it does not aggravate the destruction of the cornea, accelerate the healing of epithelial defects, resolve complications and improve visual acuity.

2. Case Reports

A 47-year-old male presented with a widening white patch on his left eye since 4 days before coming to our hospital. The left eye was injured by wood flakes 3 weeks ago. He felt a sore, red, watery left eye and blurred vision. He washed his eyes with betel leaf water, but there's no improvement. The patient complained that the left eye was still red, the vision was getting blurry, there's more eye discharge, watery eyes, difficulty in the eyelid's opening, and white spots on the black part of the left eye after two weeks. Patient went to the hospital and prescribed three eye drops, namely Levofloxacin one drop/hour on the left eye, Sodium/Potassium Chloride one drop/hour on the left eye, and 1% Atropine Sulfate eye drops one drop/8 hours on the left eye. The patient complained that the left eye was getting more red, the widening of white spots on the black part of the left eye, the vision was getting blurry, more eye discharge, watery eyes, difficulty in the eyelid's opening after four days and finally patient was referred to Dr. Mohammad Hoesin General Hospital Palembang.

His left eye visual acuity was 1/60 and not improved with pinhole. There were blepharospasm and ciliary and conjunctival injection. Corneal examination showed a cloudy cornea, a central corneal defect sized 8x6 mm with an irregular

margin, 2/3 to stromal depth, infiltrate, satellite lesion, and positive fluorescein staining at the defect margin. KOH examination demonstrated hyphae. The culture test of left corneal discharge identified a fungi species (*Curvularia sp*).

The patient was diagnosed with corneal ulcer caused by fungi (*Curvularia sp*) with a differential diagnosis of suspected bacterial infection and a combination of fungal and bacterial infection. Initial treatments include Natamycin eye drops one drop/hour for left eye, Sodium chloride 4.4 mg, Potassium chloride 0.8 mg eye drops one drop/hour for left eye, Atropine Sulfate eye drops 1% one drop/8 hours for left eye, Itraconazole 100 mg/12 hours per oral, subconjunctival injection of fluconazole 1 mL/24 hours for left eye and spooling with Ringer Lactate & povidone-iodine/12 hours. We prescribed fortified fluconazole eye drops in combination with supportive therapy for 2.5 months. The prognosis *quo ad Vitam* is *Bonam* and *quo ad Functionam* is *Dubia ad Malam*.

The patient returned on day 75th after receiving therapy, in which there has been some improvement. The patient only complained of blurred vision and glare. On ophthalmological examination, the visual acuity of the left eye improved from 6/30 to 6/21 using pinhole. Therefore we reduced the treatment dosage and the type of medication given to 4.4 mg of sodium chloride eye drops, 0.8 mg potassium chloride one drop/4 hours for left eye, and fortified fluconazole eye drops one drop/6 hours for left eye. The administration of topical fortified fluconazole was continued until 2 weeks.

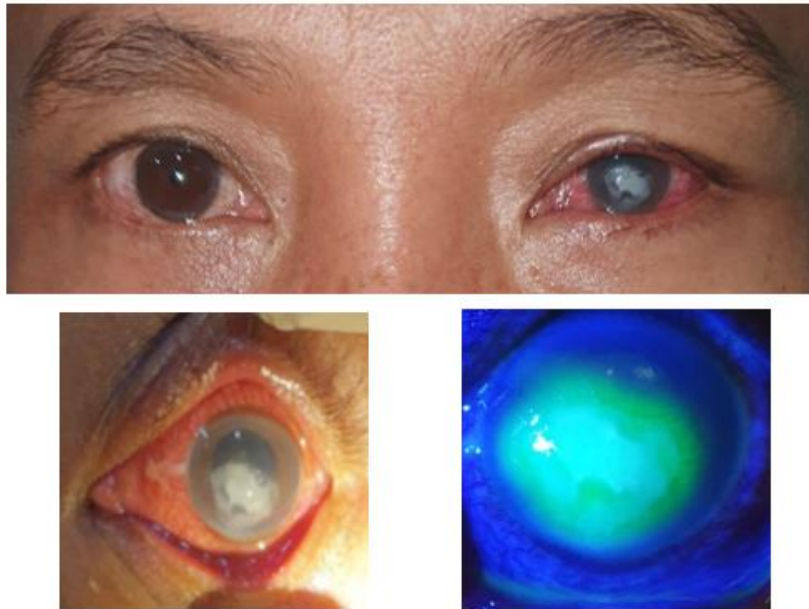


Figure 1. This figure showed ciliary and conjunctival injection. Corneal examination showed a cloudy cornea, a central corneal defect sized 8x6 mm with an irregular margin, 2/3 to stromal depth, infiltrate, satellite lesion, and positive fluorescein staining at the defect margin.

When the patient returned on day 90th after receiving therapy, the complaints has been improved. The patient only complained of blurred vision and glare. On ophthalmological examination, the visual

acuity was still the same as before, and the treatment has been stopped because there were no signs of infection.

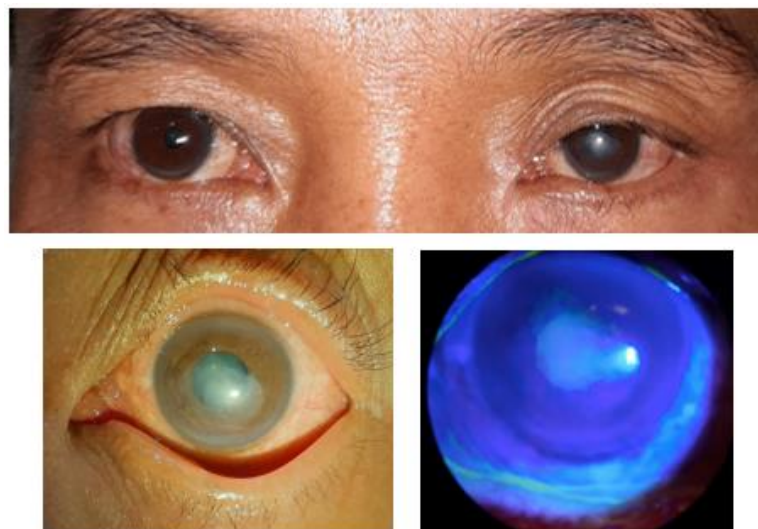


Figure 2. After treatment: cicatrix at central view, 6x6 mm in size

3. Discussion

In this report, it is known that there was vegetative trauma in the form of wood flakes and there was also a history of irrigating the eye using betel leaf water. Trauma is a risk factor for the invasion of pathogenic microorganisms to the cornea, in which from the patient's history the source of his

trauma may be potentially leads to fungal infection. In addition, two-weeks onset of traumatic events to clinical symptoms in this patient also raised suspicion of fungal infection, where the incubation time of this fungi ranges from 2-4 weeks.

In ophthalmology examination, visual acuity was 1/60. There were blepharospasm and cloudy cornea,

a central corneal defect sized 8x6 mm with an irregular margin, 2/3 to stromal depth, infiltrate, satellite lesion, and positive fluorescein staining at the defect margin. The corneal defect showed discontinuity of corneal tissue that can occur from the epithelium to the stroma, thus corneal ulcers has been confirmed as a diagnosis. Defects in the central part caused interference with the entry of light in the optic zone, as a result the patient experienced a decrease in visual acuity to 1/60. Irregular, feathery edges, which is a fibrous or hairy edge, is typical for fungal infections.

The main goal of treatments in patients with corneal ulcers is to eradicate the causal microorganisms thus the invasion of these pathogenic microorganisms will not cause damage to the deeper corneal structure and to keep the corneal repair process to a maximum and the resulting cicatrix to be minimal. It can be a primary factor in the patient's visual acuity improvement after treatment. Initial therapy in corneal ulcers includes the administration of broad-spectrum antimicrobial drugs while waiting for the results of Gram and KOH stains and culture and sensitivity testing. When laboratory examinations are interpreted, the administration of therapy could be more specific to the type of pathogenic microorganism causing this corneal ulcer. KOH examination demonstrated hyphae of *Curvularia sp* which is a pigmented-type filamentous fungal.

Initial treatments include Natamycin eye drops one drop/hour for left eye, Sodium chloride 4.4 mg, Potassium chloride 0.8 mg eye drops one drop/hour for left eye, Atropine Sulfate eye drops 1% one drop/8 hours for left eye, Itraconazole 100 mg/12 hours per oral, subconjunctival injection of fluconazole 1 mL/24 hours for left eye and spooling with Ringer Lactate & povidone-iodine/12 hours. The use of Natamycin 5% is recommended for the treatment of most cases of filamentous fungal keratitis. 5,10-13 The use of fluconazole was continued topically after we observed well-response to subconjunctival administration. This fortified fluconazole was given at a dose of 1 drop every 1 hour with a concentration of 2 mg/ml. This dose is maintained to achieve

therapeutic concentration in the cornea. The patient was also prescribed with Sulfas Atropine 1%, a cycloplegic drug administered 1 drop every 8 hours a day to dilate the pupil. This can help to prevent synechiae and relieve pain.

The initial prognosis *quo ad Vitam* is *Bonam* because vital signs are within normal values while *quo ad Functionam* is *Dubia ad Malam* due to the success of therapy depends on the timing and the accuracy of drugs administration. Structural damage to the cornea due to corneal ulcers will also determine the prognosis *quo ad Functionam*, if the depth of the corneal ulcer has reached deeper structure, the improvement in visual acuity will not likely to be achieved because the corneal transparency has been changed. It occurred to this patient where the corneal damage involved 2/3 of the stromal depth. In the stroma, the wound repair process will form a network of fibroblasts that are arranged irregularly so that a cyclone is formed which makes the cloudy cornea. This turbidity makes the rays that enter through the optical zone cannot be transmitted optimally. After the eradication of the etiological microorganisms has been successful, the visual function remains difficult to achieve the initial baseline vision before the corneal ulcer occurred.

When the patient returned on day 75th after receiving therapy, there was a significant examination result where the clinical symptoms began to decrease and accompanied by an increase in vision. On corneal examination, a negative fluorescent test was also obtained. This indicates that the corneal epithelialization process has been complete and left a corneal scar. Afterwards, we tapered the dose of the previous therapy and continued the administration of fortified fluconazole. The reduced doses were given to keep the infection process from reappearing.

When the patient returned on day 90th after receiving therapy, there has been some improvement. The patient only complained of blurred vision and glare. On ophthalmological examination, the visual acuity was still the same as the previous month. This is due to the formation of cicatrix on the cornea covering the visual axis. On corneal examination, a

negative fluorescent test and cicatrix measured 6x6 mm in size in the center cornea were found. The process of corneal reepithelialization remodelling has occurred optimally and the treatment can be stopped.

Imidazoles work by inhibiting the biosynthesis of ergosterol from fungal cell walls, through action on enzymes that depend on cytochrome P450. It results in destabilization and leakage of the cell membrane. *Curvularia* sp belongs to the dematiaceous fungi family. Clinical manifestations include raised lesions and hairy margins; hypopyon is rare, and the prognosis is favorable. Fluconazole (2 mg/ml) is available for injection and is a well-tolerated eye drop. Intravenous fluconazole can be used as a topical treatment and can be administered subconjunctivally at the same concentration.^{3,9,14}

4. Conclusion

Fortified fluconazole eye drops (2 mg/ml) can be an alternative and additional therapy for deep fungal keratitis, especially for *Curvularia* sp.

5. References

1. Cantor LB, et al. Basic and clinical science course: Section 8; External Disease and Cornea. San Francisco: American Academy of Ophthalmology 2019; 273-276p.
2. Pan XJ, Jiang T, Zhu H, Liu PP, Zhou ZY, Mao AJ. Corneal infection in Shandong peninsula of China: a 10-year retrospective study on 578 cases. *Int J Ophthalmol.* 2016;9(1):53-57. Published 2016 Jan 18. doi:10.18240/ijo.2016.01.09
3. Ahmed F, House RJ, Feldman BH. Corneal Abrasions and Corneal Foreign Bodies. *Prim. Care.* 2015 Sep;42(3):363-75p
4. Prajna L, et al. Fungal Corneal Ulcers Clinical Features & Laboratory Identification Methods. India: Jaypee Brothers Medical Publishers. 2008; 16-27p & 102-8p.
5. Cantor LB, et al. Basic and clinical science course: Section 8; External Disease and Cornea. San Francisco: American Academy of Ophthalmology. 2019; 182-203p
6. Gintjee TJ, Donnelley MA, Thompson III GR. Aspiring Antifungals: Review of Current Antifungal Pipeline Developments. *J. Fungi* 2020, 6, 28; doi:10.3390/jof6010028
7. Panda A, et al. *Ocular Infections.* India: Jaypee Brothers Medical Publishers. 2008; 21-59p.
8. Cantor LB, et al. Basic and clinical science course: Section 2; Fundamental and Principles Ophthalmology. San Francisco: American Academy of Ophthalmology. 2019; 42-46p & 169-172p
9. Mannis MJ, et al. *Corneal Fundamental, Diagnosis and Management.* London. 2017; 229-273p
10. Foster CS, et al. *The Cornea Scientific Foundations and Clinical Practice.* USA: Lippincott Williams & Wilkins. 2005; 3-22p
11. Copeland RA, et al. *Principles and Practice of Cornea.* London: Jaypee Brothers Medical Publishers. 2013; 26-81p
12. Tabbara KF, et al. *Ocular Infections.* New York: Springer Heidelberg. 2014; 84-7p.
13. Duval B, Kershner R. *Ophthalmic Medications and Pharmacology.* USA: SLACK Incorporated. 2009; 75-88p
14. Colby K, et al. *Foundations of Corneal Disease: Chapter; Fungal Keratitis.* Switzerland: Springer Nature Switzerland AG. 2020. 37-46p.