

Sriwijaya Journal of Ophthalmology

Journal Homepage: <https://sriwijayaophthalmology.com/index.php/sjo>

Comparison of Copper Level and Color Vision in Pulmonary Tuberculosis Patients Before and After Ethambutol Treatment in Category I and II

Febria Restissa^{1*}, Ahmad Rasyid¹, Devi Azri Wahyuni¹

¹Department of Ophthalmology, Faculty of Medicine, Universitas Sriwijaya, Palembang, Indonesia

ARTICLE INFO

Keywords:

Color vision
Copper (Cu²⁺)
Ethambutol
Farnsworth Munsell 100 Hue
Tuberculosis

Corresponding author:

Febria Restissa

E-mail address:

febriarestissa@gmail.com

All authors have reviewed and approved the final version of the manuscript.

<https://doi.org/10.37275/sjo.v3i1.39>

ABSTRACT

Introduction: to determine the correlation between duration of ethambutol and copper levels in serum with color vision disorder examined with Farnsworth Munsell 100 Hue (FM100) in patients with tuberculosis. **Methods:** This study was an explorative observation of 20 samples during November 2017 - January 2018 period. Comparative analysis using independent t-test, paired t-test, Wilcoxon test and Mann-Whitney test, while correlation analysis using Spearman's test and Pearson's test. **Results:** There was a significant difference of FM100 value before and after in category I (p=0.000) with increase of total error value 11.80+5.31 or category II (p=0.000) with increase of total error value 15.00+7.41. There was significant difference of Cu²⁺ level before and after in category I (p=0.005) with decrease of Cu²⁺ level 15.57+5.04 mg/dL or category II (p=0.005) with decrease of Cu²⁺ level 31.66+7.35 mg/dL. There was significant correlation between color vision and duration of ethambutol (p=0.000), but there was no significant correlation of Cu²⁺ with color vision (p>0.05). **Conclusion:** The duration of Ethambutol was related to changes in color vision examined with FM100.

1. Introduction

Tuberculosis is one of public health problem. One third of population is infected by Mycobacterium tuberculosis. World Health Organization (WHO) estimated 2-4 people are infected with TB every second, and nearly 4 people every minute died from TB. In Indonesia, there are a quarter million cases and 140,000 deaths occur annually, and TB is number one killer among infectious diseases and number three after heart disease and acute respiratory disease in all ages. Data taken from the 2014 Palembang City Health Profile shows the number of cases of pulmonary TB was 1972 cases.¹⁻⁵

Ethambutol is used in initial TB therapy. Its side effects, optic neuropathy, have been known since 1960. Optic neuropathy depends on dose and duration of ethambutol treatment. This side effect

of ethambutol can occur in patients who have used the least medication 2 months, whereas symptoms generally appear between 4 months to one year. Kumar, reported that ethambutol toxicity was 42.2% within 10-12 months after giving ethambutol. Robert reports that administration of ethambutol 15 mg / kg / day for 4-8 months of therapy cause optic neuropathy in 1.6% of cases and when given at a dose 25 mg / kg / day causes optic neuropathy in 2.48% of cases.^{4-5,7,8-9}

Toxicity of ethambutol using is still hypothetical. This hypothesis try to prove toxicity occurs through oxidative phospholiration disorders in Mitochondria of Retinal Ganglion Cells (RGCs) are also disrupted. The latest study conducted on the role of Cu in ethambutol toxicity. Cu triggers mitochondrial apoptosis in RGCs.^{8-9,15-26}

Copper (Cu) is an essential trace element. It is an important element in growth and development almost in all microorganisms. In the eye, Cu plays a role in maintaining vision.²⁶⁻²⁹ Cu is one of element in ethambutol. Cu can interfere oxidative phosphorylation and mitochondrial functions. Long-term effect of Cu is induce apoptosis. Color vision function i can also occur if there is a decrease in serum levelss disturbed in patients with pulmonary tuberculosis. In several studies conducted by Koyonagi et al, Cu serum levels in patients who using anti-tuberculosis drugs is significantly decreased. Abdouasser et al reported that after 10 days of Ethambutol treatment, Cu levels in pulmonary tuberculosis patients were significantly decreased.²⁷⁻³¹

2. Methods

This is a prospective study that aim to assess the ratio between serum copper levels and visual color impairment in patients with pulmonary tuberculosis before and after administration ethambutol in category I and category II Tb therapy. This study was undertaken in November 2017 to January 2018. There were 20 patients who met the inclusion and exclusion criteria. The

protocol has been approved of Ethics Committee, Faculty of Medicine Sriwijaya University.

After an interview to asesess clinical data, we perform ophthalmological examination. Color vision function is assessed by Farnsworth Munsell 100 Hue examination. Examination of Copper serum level is by taking blood samples as much as 3 cc and examined at the Biomolecular Laboratory, Faculty of Medicine Sriwijaya University.

All data are described in univariate table and graph. Data analysis was performed using SPSS. We use Spahiro Wilk to assess normality distribution. Comparison of each group was tested using Mann-Whitney test. Correlation in this study was test by Pearson test (parametic data) and Spearman test (non parametric).

3. Results

In the period November 2017 to January 2018., there were 20 patients who met the inclusion and exclusion criteria. Examination of color vision with Farnsworth Munsell 100 Hue proved the highest color discrimination is obtained in 12 subjects (60%) and others had average color discrimination as many as 8 subjects (40%).

Tabel 1. Comparison of Copper Level Before Ethambutol Treatment.

	Cu Serum	P*
First Category	80.40+3.07 µg/dL	0.07
Second Category	75.62+5.49 µg/dL	

Tabel 2. Comparison of Copper Level After Ethambutol Treatment.

	Cu Serum	P*
First Category	64.83+5.39 µg/dL	0.00
Second Category	43.96+5.94 µg/dL	

Table 3. Comparisson FM100 Examination Before and After Ethambutol Therapy

	Before Treatment	After Treatment	ΔFM100	
First Category	11.30+3.89	23.10+7.79	11.80+5.31	0.000
Second Category	24.40+6.72	39.40+8.38	15.00+7.41	0.000

Paired T test (p < 0.05)

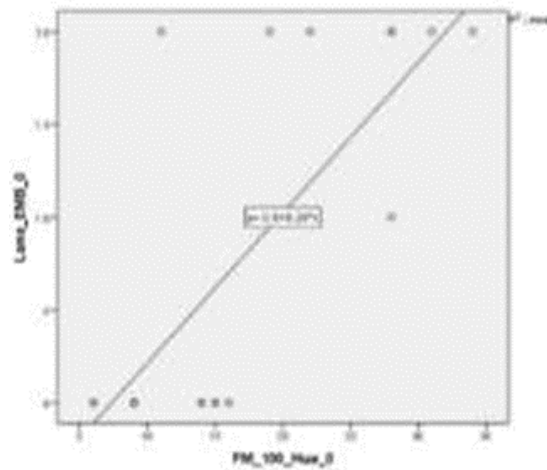


Figure 1. Correlation of FM100 examination before and after ethambutol therapy

Correlation between FM100 examination before and after ethambutol therapy was assessed by Pearson's correlation test. Obtained the value of $r = 0.580$. P value 0.000 means there is a moderate strength correlation and has a positive statistically significant result. There was significant correlation between color vision and duration of ethambutol ($p=0.000$), but there was no significant correlation of Cu^{2+} with color vision ($p>0.05$).

4. Discussion

In this study, Cu levels before and after ethambutol therapy in category 1 groups decrease $15.57 + 5.04 \mu\text{g} / \text{dL}$. Based on the analysis of the Wilcoxon test, it found significant differences in Copper content before and after on category 1 with p value = 0.005. In the category 2 group, Cu levels before and after ethambutol therapy decrease of $31.66 + 7.35 \mu\text{g} / \text{dL}$. Based on the Wilcoxon test analysis, it shows significant differences Cu levels before and after in category 2 with p value = 0.005. Based on non-parametric comparison test, Mann-Whitney test, it shows significant differences after copper levels between the category I groups and category II with p value = 0,000. This study also found an average the value of Cu level after ethambutol therapy in the category I was $64.83 \pm 5.39 \mu\text{g} / \text{dL}$ and in the category II was $43.96 \pm 5.94 \mu\text{g} / \text{dL}$.

Ethambutol interferes oxidative phosphorylation by not binding copper in mitochondria. This situation change mitochondria

potential membrane, Research carried out the role of Cu in ethambutol toxicity. It was found that Cu plays a role in the toxicity of ethambutol by triggering mitochondrial apoptosis in RGCs.²⁶⁻²⁹

To obtain the correlation between serum Cu level and Farnsworth Munsell 100 Hue, we performed Spearman's and Pearson's Correlations. The aim is to find out correlation between serum Cu level with color vision impairment. The results are not significant correlations serum Cu level with color vision impairment before and after the category 1 or 2 treatment. Ray's study proved changes serum Cu level in Tb patient. After completing treatment, a significant decreasing in serum Cu levels can occur. Koyonagi et al examined serum Cu and zinc levels in patients with pulmonary tuberculosis, there was decreasing serum Cu level in patients who use. As a metal chelator found in ethambutol, Cu and Zinc can interfere with oxidative phosphorylation and mitochondrial function, and the synthesis is divided into two complexes. Both groups has function in ATP formation which functions as synthesis and metabolism in mitochondria. Damage in the formation of long-term ATP and a buildup of reactive oxygen species (ROS) cause apoptosis.^{2,26,30}

5. Conclusion

The duration of Ethambutol was related to changes in color vision examined with FM100.

6. References

1. The Global Plan to Stop TB, 2006–2015. Geneva, World Health Organization. 2006 (WHO/HTM/STB/2006.35)
2. International standards for tuberculosis care, 2nd ed. The Hague, Tuberculosis Coalition for Technical Assistance. 2009.
3. Carlos, J. Anandi, M., and Francoise P. 2007. MODS assay for the diagnosis of tuberculosis. *New England Journal of Medicine* 356:188-189.
4. WHO. 2015. Global Tuberculosis Report 2015
5. Perhimpunan Dokter Paru Indonesia. Pedoman penatalaksanaan TB. Jakarta.
6. Depkes RI. 2008. Pedoman nasional penanggulangan tuberkulosis. Jakarta : Gerdunas TB. Edisi 2 hal. 4-
7. Depkes RI. 2011. TBC masalah kesehatan dunia. Jakarta: BPPSDMK.
8. Tetiana, Mira. Azri Wahyuni, Devi. Saleh, Irsan. Rasyid, Ahmad. 2016. Korelasi antara lama pemberian ethambutol dan kadar zinc dalam serum dengan penglihatan warna pada penderita tuberkulosis paru. Tesis. Departemen Kesehatan Mata; Universitas Sriwijaya Palembang.
9. Nugroho, Agus. Azri Wahyuni, Devi. Saleh, Irsan. Rasyid, Ahmad. 2016. Defek lapangan pandang pada penderita tuberkulosis paru yang mendapat terapi ethambutol. Tesis. Departemen Kesehatan Mata; Universitas Sriwijaya Palembang.
10. Retno AW. Patofisiologi, diagnosis dan klasifikasi tuberkulosis. Departemen Ilmu Kedokteran Komunitas, Okupasi dan Keluarga Fakultas Kedokteran Universitas Indonesia. Jakarta.
11. Alvin K. Ocular toxicity of ethambutol. *The Hongkong Medical Diary* 2006.
12. Internal Guidelines of the Tuberculosis and Chest Service of Department of Health. Preventive measures against drug-induced ocular toxicity during anti-tuberculosis treatment. 2002.
13. Mohammad A, et al. Studying the effect of zinc and copper on cellular immunity in tuberculosis patient. *Medical Journal of Babylon. Iraq.* 2011.
14. Wong Jasper, et al. Detection of early ethambutol ocular toxicity. Ishihara pseudoisochromatic plates versus the Farnworth D-15 Hue test. *Journal Neurophysiology and neurological disorder*; 2013. 15.
15. WA Kaimbo, et al. Color vision in 42 Congolese patients with tuberculosis receiving ethambutol treatment. *Journal Belge Ophthalmology*; 2002.
16. Emerson M. Cruz, et al. Color-vision abnormalities among patients undergoing tuberculosis treatment. *Journal Philippine Academy of Ophthalmology*; 2010.
17. Rao Lavana V, et al. Ocular toxicity of anti-tuberculous treatment. *Kerala Journal of Ophthalmology*; 2006.
18. Joubert P.H. et al. Subclinical impairment of colour vision in patients receiving ethambutol. *British Journal Clinical Pharmacology*; 1986.
19. Jan Michael R, et al. Efficacy of vitamin supplementation in preventing color vision abnormalities among patients undergoing DOTS for tuberculosis. *Philippine Journal Ophthalmology*; 2013.
20. RYC Chan, AKH Kwok. Ocular toxicity of ethambutol. *Hongkong medical journal*; 2006.
21. Menon V, et al. Prospective evaluation of visual function for early detection of ethambutol toxicity. *Britist Journal of Ophthalmology*; 2009.
22. SB Kokkada, et al. Ocular side effect of anti tubercular drugs. *Katmandu University Medical Journal*; 2005.
23. Alfredo A, Sadun. Mitochondrial optic neuropathies. *Annual Meeting Syllabus. California* 2012.

24. Sahar P, Peggy F. Examination of color vision. The Journal of Clinical Examination; England 2008.
25. Elizabeth M. Grace, Andrew G. Lee. Ethambutol toxicity and optic neuropathy; University of Iowa Health Care Ophthalmology and Visual Sciences; 2007.
26. Paul H. Philips. Toxic and deficiency optic neuropathies. Chapter 10.
27. Leary Scot C, et al. Pulling the plug on cellular copper: The role of mitochondria in copper export. Departement of Medicine and Biochemistry; USA; 2009.
28. Bogden John, et al. Effect of pulmonary tuberculosis on blood concentration of copper and zinc. Department of Preventive Medicine and Community Health. New Jersey; 1976.
29. K Elvina, et al. Poor micronutrient status of active pulmonary tuberculosis patients in Indonesia. The Journal of Nutrition; 2000.
30. Monique van Lettow, et al. Micronutrient malnutrition and wasting in adult with pulmonary tuberculosis with and without HIV co-infection in Malawi; USA; 2004.
31. Hassan G, et al. Status of copper in pulmonary tuberculosis. Journal Infect Dev Ctries; India; 2009.
32. Ghose Supriyo, et al. A simple modification of the Farnsworth Munsell (FM) 100 hue test for much faster assessment of colour vision. Optic/ Refraction/ Contact Lenses Session. New Delhi.
33. Cho HW. Farnsworth-Munsell 100 hue test in diagnosis of ocular toxicity from ethambutol. Journal Korean Ophthalmol; Korea; 1977.
34. Trusiewicz D. Farnsworth 100 hue test in diagnosis of ethambutol induced damage to optic nerve. Ophthalmologica; 1975.
35. Jasper K W wong, et al. Detection of early ethambutol ocular toxicity: Ischihara pseudoisochromatic plates versus the Farnsworth D-15 hue test. Journal Neurophysiol Neurol Disorder; 2013.
36. Twinkle Parmar, et al. Colour vision reversired: Dhelhi Journal Ophthalmolol; New dhelhi; 2014