



Sriwijaya Journal of Ophthalmology

Journal Homepage: <https://sriwijayaophthalmology.com/index.php/sjo>

Management of Clinically Significant Macular Edema

Elisa Taurisia^{1*}, Ramzi Amin¹, AK Ansyori¹

¹Department of Ophthalmology, Faculty of Medicine, Universitas Sriwijaya, Palembang, Indonesia

ARTICLE INFO

Keywords:

Macular edema
Clinically significant
Treatment
Management

Corresponding author:

Febria Restissa

E-mail address:

elisa.taurisia@gmail.com

All authors have reviewed and approved the final version of the manuscript.

<https://doi.org/10.37275/sjo.v3i1.23>

ABSTRACT

Introduction: Macular edema is the most common cause of visual impairment in NPDR. Macular edema occurs due to increased perifoveal capillary permeability resulting in fluid accumulation in the macular area. Control of blood sugar levels is an important factor in the management of diabetic retinopathy because it can reduce the risk of progression of retinopathy, decreased vision and macular edema. Currently, focal photocoagulation argon lasers are the only proven long-term treatment for diabetic macular edema. **Case presentation:** Reported case of a 55-year-old woman, address outside the city, came to the Dr. Mohammad Hoesin General Hospital Palembang eye clinic with complaints of blurred vision since ± 6 months ago. three days ago, the patient went to an internal medicine clinic and was said to have high blood sugar and blood pressure. The views of both sufferers' eyes are increasingly blurred. The treatment chosen for this patient was intravitreal anti-VEGF (bevacizumab) injection in the right and left eye to reduce vascular permeability thereby reducing macular edema. 1-time bevacizumab injection has only a short-term optimal effect so re-injection is needed at 4-6 weeks intervals. **Conclusion:** A clinically significant case of macular edema (CSME) has been reported that is treated with intravitreal anti-VEGF combined with focal photon photocoagulation laser. The patient's final vision 1 week after the focal photocoagulation argon laser was performed showed improvement.

1. Introduction

The prevalence of diabetic retinopathy in diabetics increases with age and duration of diabetes. Nearly 99% of people with type 1 diabetes and 60% of type 2 develop diabetic retinopathy after suffering from diabetes for 20 years. Three-point six percent of people with type 1 diabetes (less than 30 years old) and 1.6% of people with type 2 diabetes (aged 30 years or more) experience blindness due to diabetic retinopathy. Macular edema is one of the major causes that threatens vision in diabetic retinopathy^{1,2,3,4}

Diabetic retinopathy is classified into early stage, namely non-proliferative diabetic retinopathy (NPDR), and advanced stage, namely proliferative diabetic retinopathy (PDR). The degree of NPDR is divided into mild, moderate, severe. PDR degrees are divided into early, high- risk, and advanced. Macular edema is the most common cause of visual impairment in NPDR. Macular

edema occurs due to increased perifoveal capillary permeability resulting in fluid accumulation in the macular area.^{1,2,5,6}

The main goal of management of diabetic retinopathy is to slow down and prevent complications. Control of blood sugar levels is an important factor in the management of diabetic retinopathy because it can reduce the risk of progression of retinopathy, decreased vision and macular edema. Currently, focal photocoagulation argon lasers are the only proven long-term treatment for diabetic macular edema. Several new studies evaluate the role of anti-VEGF (Vascular Endothelial Growth Factor) for the treatment of retinal neovascularization and exudative processes in diabetic retinopathy. Large multicenter studies show that intravitreal anti-VEGF injections every month for 3 months followed by macular laser action immediately after or within minggu24 weeks

can result in improved vision and a very significant reduction in macular thickening.^{1,2,3,7}

Report a case of *Clinically Significant Macular Edema (CSME)* which is managed with intravitreal anti-VEGF and focal photon photocoagulation laser.

2. Case Reports

Identification A woman, Mrs. S., aged 55, address outside the city, came to the Palembang RSMH eye clinic on November 3, 2014 with complaints of blurred vision. Medical record number: 861841. Amnesia (Auto-anamnesis dated November 3, 2014). Main Complaints: blurred vision of both eyes. Travel history of the disease: Since ± 6 months ago sufferers complained of blurred vision. red eye (-), pain in the eye (-), history such as seeing flying objects (-), headache (-), nausea (-), vomiting (-), history of vision such as seeing in a tunnel (-), viewing history such as a rainbow (-), viewing history such as being covered

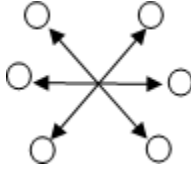
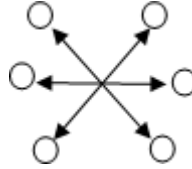
by a curtain (-), viewing history such as seeing a black shadow in the middle (-), history of seeing straight objects so bent (-), history of seeing objects become smaller or enlarged (-), history of trauma (-). The eyes are blurry with each other.

± 3 days ago, the patient went to an internal medicine clinic and it was said that the patient's blood sugar and blood pressure were high. The views of both eyes of the patient are increasingly blurred (+). Patients were consulted to RSMH eye clinic. Past Disease History: History Glasses (-), History of diabetes (+) since ± 10 years, treatment by taking irregular diabetes medication. History of high blood pressure (+) since ± 10 years, treated by taking high blood pressure-lowering drugs regularly. History of smoking is denied. History of allergy is denied. History of visual impairment from birth or since childhood (-). History of other systemic diseases since birth or since childhood (-). Family Disease History: Family history of the same disease is denied.

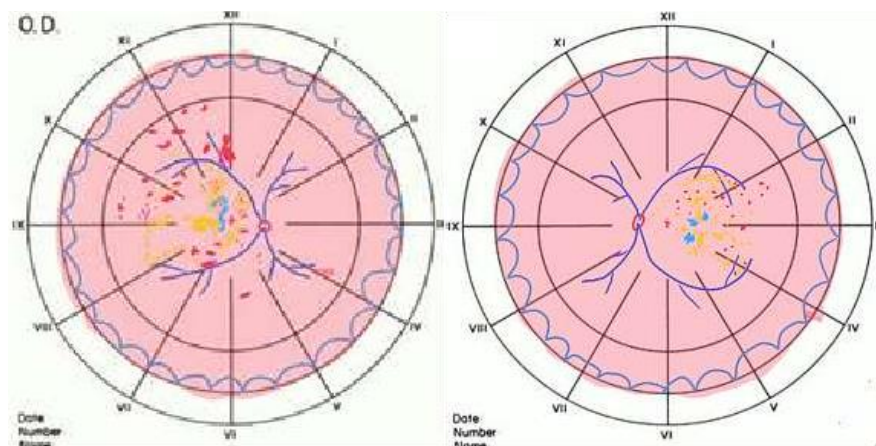
Physical examination of generalist status:

General Condition	: Good	Pulse	: 80x/minute
Awareness	: Compos Mentis	Respiratory rate	: 18x/ minute
Blood Pressure	:160/100 mmHg	Temperature	: 36,8 °C

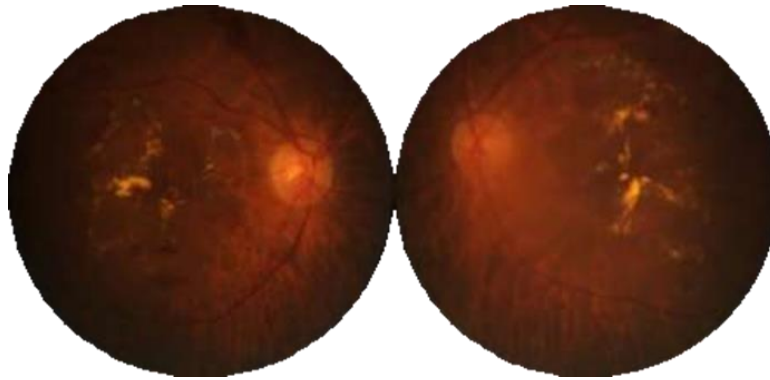
Ophthalmologic status:

	OD	OS
Vision	3/60 Ph (-)	3/60 Ph (-)
TIO	18,5mmHg	18,5mmHg
KBM	orthophoria	
GBM		
Palpebra	Normal	Normal
Conjunctiva	Normal	Normal
Cornea	Clear	Clear
BMD	Medium	Medium
Sliced	Good Image	Good Image
Pupil	B, C, RC L/TL (+) N, Ø 3 mm	B, C, RC L/TL (+) N, Ø 3 mm
Lens	Clear	Clear
Posterior Segment	RFOD (+)	RFOS (+)
Papil:	Round, firm boundary, normal red color, c / d: 0.3, a / v: 1/3.	Round, firm boundary, normal red color, c / d: 0.3, a / v: 1/3.
Macula:	Fovea reflex (+) ↓, visible thickening of the retina and hard exudates (+) within 500 µm from the central macula	Fovea reflex (+) ↓, visible thickening of the retina and hard exudates (+) within 500 µm from the central macula
Retina:	Sclerotic artery contours, microaneurysms (+), dot bleeding (+), blot (+), flame shape (+), hard exudates (+) <4 quadrants	Sclerotic artery contours, microaneurysms (+), dot bleeding (+), blot (+), flame shape (+), hard exudates (+) <4 quadrants

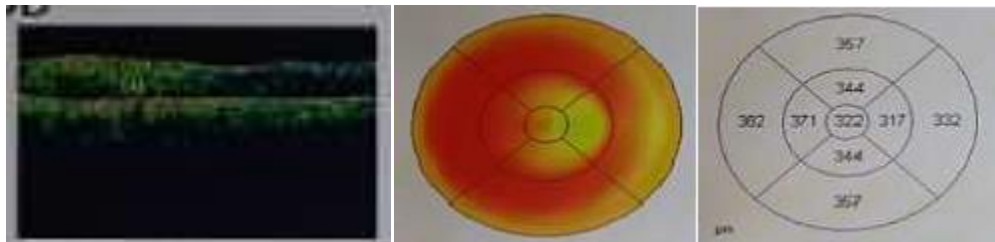
Retina Drawing ODS:



Fundus photo supporting examination



Impression: Moderate NPDR + CSME ODS, Oculi Dekstra:



Retinal thickness: Fovea 322 μm , Central Zone 317-371 μm , Perifoveal 332-382 μm , Hyporeflexivity found in subretina and thickening of the retina and

loss of depression fovea. Impression of OS mulaular endema

Laboratory Results Table

Examination	Results	Reference	Unit
Hematologist			
Hemoglobin (HGB)	15	12-16	g/dl
Erythrocytes (RBC)	4.29	4.0-5.0	$10^6 / \text{mm}^3$
Leukocytes (WBC)	6.8	5-10	$10^3 / \text{mm}^3$
Hematocrit	41	37-43	Vol %
Platelets (PLT)	243	200-500	$10^3 / \text{ul}$
LED	27	< 38	mm/jam
Bleeding time	3	1-3	Minute
Freezing time	9	9-15	Minute
Calculate type			
B/E/Nb/Ns/L/M	0/6/1/59/26/8		%
Glucose in the time	270	70-200	mg/dl
Clinical Chemist			
Total Cholesterol	280	< 200	mg/dl
HDL Cholesterol	56	> 65	mg/dl
LDL Cholesterol	165	< 150	mg/dl
Triglyceride	232	40-200	mg/dl
Ureum	20	15-39	mg/dl
Creatinine	0.7	0.6-1.0	mg/dl

The working diagnosis is Moderate NPDR ODS + CSME ODS, type 2 DM + stage 2 hypertension + dyslipidemia. Management is informed consent, admission to hospital / hospitalization, intravitreal OD anti-VEGF (bevacizumab) injection, pro intravitreal anti-VEGF injection (bevacizumab), pro-argon laser photocoagulation with focal ODS, 1x1 tablet antioxidant. The prognosis is Quo ad Vitam: bonam, Quo ad functionam: dubia ad bonam.

3. Discussion

Reported case of a 55-year-old woman, address outside the city, came to the Palembang RSMH eye clinic with complaints of blurred vision since ± 6 months ago. three days ago, the patient went to an internal medicine clinic and was said to have high blood sugar and blood pressure. The views of both sufferers' eyes are increasingly blurred. Patients are advised to consult with the eye clinic RSMH. From the history of the disease first obtained a history of diabetes (+) since ± 10 years, treatment by taking irregular diabetes medication. History of hypertension (+) since ± 10 years, treated by taking high blood pressure-lowering drugs regularly. History of high cholesterol (+) since ± 5 years.

On ophthalmology examination, anterior segment is found within normal limits. Funduscopic examination and fundus photos of the right and left posterior segments show the comparison of arteries and veins in papules 1: 3, this shows the presence of vascular sclerotic. In the macula the Fovea (+) ↓ reflex, thickening of the retina and hard exudates (+) within 500 μm from the central macula are in accordance with CSME criteria. In the retina, micro-aneurisms (+), dot (+) bleeding, blot (+), flame shape (+), hard exudates (+) are less than 4 quadrants, which can be classified as Moderate NPDR ODS. OCT examination revealed subretinal hyporeflectivity and thickening of the retina and loss of depression fovea which showed macular edema in the right and left eye. From the initial blood laboratory examination, it was found that blood glucose increased at 270 mg / dl, blood pressure 160/100 mmHg and increased total cholesterol (280 mg / dl), LDL cholesterol (165 mg / dl), and triglycerides (232 mg / dl). All are

factors that can increase the progression of diabetic retinopathy and macular edema.

Diagnosis is based on history taking, ophthalmology examination, OCT investigation and blood laboratory above. The diagnosis of this patient is Moderate NPDR ODS and CSME ODS.

The main goal of management of diabetic retinopathy is to slow down and prevent complications. This patient was given informed consent regarding diagnosis, management and methods, the benefits and goals of therapy, as well as the importance of controlling blood sugar levels, blood pressure, blood lipids, body mass index (BMI), lifestyle changes, exercise habits, and avoiding smoking because they can reduce the risk of retinopathy progression, decreased vision and macular edema. The treatment chosen for this patient was intravitreal anti-VEGF (bevacizumab) injection in the right and left eye to reduce vascular permeability thereby reducing macular edema. 1-time bevacizumab injection has only a short-term optimal effect so re-injection is needed at 4-6 weeks intervals. Anti-VEGF (bevacizumab) injection in this patient is done every month for 3 months. After anti-VEGF injection for 3 months, one week later, argon laser photocoagulation of the focal in the right and left eye because based on ETDRS, management of CSME with argon laser focal photocoagulation can reduce the risk of moderate visual loss, increase vision repair, reduce the occurrence of subretinal fibrosis due to the number of hard drives exudates in the macula and only causes minor visual field defects. At present, focal photocoagulation laser argon is also the only proven long-term treatment for diabetic macular edema. Large multicenter studies show that intravitreal anti-VEGF (ranibizumab) injections every month for 3 months followed by macular laser treatment immediately thereafter (3-10 days) or ≥ 24 weeks apart can result in improved vision and reduced macular thickening significantly compared to management only laser immediately. In this patient the anti-VEGF used is bevacizumab because the patient uses government health insurance which at the time of the treatment the insurance only finances the use of bevacizumab as

the only anti-VEGF. However, the patient's final vision 1 week after the argon focal photocoagulation laser in the right and left eye also showed improvement. The initial vision of the right and left eye 3/60 becomes 6/30. These patients are routinely controlled for treatment at an internist in their area so that follow-up blood sugar, blood pressure, and cholesterol levels are always controlled and can help reduce the risk of progression of retinopathy, macular edema and decreased vision. Patients are still advised to routinely control an ophthalmologist every 2 months. If when the control progresses diabetic retinopathy, macular edema, and a decrease in vision, anti-VEGF injection can be done again.

Patients with controlled blood sugar and blood sugar levels have a better prognosis because they reduce the risk of heart attack, stroke, DM nephropathy and death and reduce the risk of progression of retinopathy, decreased vision and macular edema.

This case report only evaluates the treatment results from improved vision and reduction of exudate and retinal bleeding from ophthalmoscope examination and fundus photographs. The weakness of this case report is that there is no OCT examination to assess the reduction in macular thickness after treatment.

4. Conclusion

A clinically significant case of macular edema (CSME) has been reported that is treated with intravitreal anti-VEGF combined with focal photon photocoagulation laser. A woman aged 55 years, with complaints of vision both eyes blurred since ± 6 months ago. When you go to the eye clinic for blood sugar levels when, blood pressure and blood cholesterol levels increase. From the results of fundoscopic examination, thickening of the retina and *hard exudates* within 500 µm from the central macula in the right and left eye was in accordance with CSME criteria.

The treatment chosen for this patient was intravitreal anti-VEGF (bevacizumab) injection in the right and left eye every month for 3 months. One week later, the focal photocoagulation laser was performed

on the right and left eyes. The patient's final vision 1 week after the focal photocoagulation argon laser was performed showed improvement. The initial vision of the right and left eye 3/60 becomes 6/30. Blood pressure, blood sugar levels, and cholesterol at follow-up are always controlled, so they can help reduce the risk of progressive retinopathy, macular edema and decreased vision.

5. References

1. Skuta GL, Cantor LB, Weiss JS, et al. Retinal Vascular Disease. Retina and Vitreus. American Academy of Ophthalmology Section 12. 2011-2012; 107-180.
2. Kanski JJ. Retinal Vascular Disease. Clinical Ophthalmology A Systematic Approach. 2011; 533-592.
3. Frank RN. Etiologic Mechanisms in Diabetic Retinopathy. Retinal Vascular Disease. Retina. 2006;1241-1270.
4. Williams GA. Diabetic Retinopathy. Medical Retina. 2012; 90-98.
5. Dharmalingam M. Review Diabetic Retinopathy – Risk Factors and Strategies in Prevention. International Journal of Diabetic in Development Countries. 2003; 10-13.
6. Chew EY, Ferris III FL. Nonproliferative Diabetic Retinopathy. Retinal Vascular Disease. Retina. 2006; 1271-1284.
7. Faghihi H et al. Intravitreal bevacizumab versus combined bevacizumab-triamcinolone versus macular laser photocoagulation in diabetic macular edema. European Journal of Ophthalmology. 2008; 941-948.
8. Suhardjo SU, Hartono. Anatomi Mata dan Fisiologi Penglihatan. Ilmu Kesehatan Mata. 2012; 1-18.
9. Skuta GL, Cantor LB, Weiss JS, et al. Basic Anatomy. Retina and Vitreus. American Academy of Ophthalmology Section 12. 2011-2012; 7-18.
10. Skuta GL, Cantor LB, Weiss JS, et al. The Eye. Fundamentals Principles of

- Ophthalmology. American Academy of Ophthalmology Section 2. 2011-2012; 41-86.
11. Ryan SJ. Function and Anatomy of The Mammalian Retina. *Retina*. 2013; 393-434.
 12. Charles ER, Albert A, Constantin JP. Ocular Circulation. *Nutrition of The Eye. Adler's Physiology of The Eye*. 2011; 243-273.
 13. Archer DB, Gardiner TA, Stitt AW. Functional Anatomy, Fine Structure, and Basic Pathology of The Retinal Vasculature. *Retinal Vascular Disease*. 2007; 35-55. <http://www.medicine.uiowa.edu/eye/ophthalmology>.
 14. Rahman K, Kartasasmita A, Heksan. *Pedoman Penanganan Retinopati Diabetika*. 2013.
 15. Bloom SM, Brucker AJ. Principles of Photocoagulation. *Laser Surgery of Posterior Segment*. 1997; 3-27.
 16. Lacono P, Parodi MB, Bandello F. Antivascular Endothelial Growth Factor in Diabetic Retinopathy. 2010;39-53.
 17. Karth PA, et al. Bevacizumab. 2014. Available at www.eyewiki.aao.org/Bevacizumab