



Sriwijaya Journal of Ophthalmology

Journal Homepage: <https://sriwijayaophthalmology.com/index.php/sjo>

Management of Regmatogen Retinal Ablation by Buckle Sclera and Cryotherapy

Faneisha^{1*}, AK Ansyori¹, Ramzi Amin¹

¹Department of Ophthalmology, Faculty of Medicine, Universitas Sriwijaya, Palembang, Indonesia

ARTICLE INFO

Keywords:

Regmatogen
Retinal ablation
Buckle sclera
Cryotherapy

Corresponding author:

Faneisha

E-mail address:

faneisha@gmail.com

All authors have reviewed and approved the final version of the manuscript.

<https://doi.org/10.37275/sjo.v3i1.21>

ABSTRACT

Introduction: The most common type is regmatogen retinal detachment (rhegmatogenous retinal detachment), which is a result of the process of tearing of the retinal layer. The principle of operative management of retinal detachment is to reattach the detached layer of the retina by previously identifying and closing if there is a retinal tear and releasing traction from vitreoretina. Actions can include sclera buckle, pars plana vitrectomy and pneumatic retinopexy. The consideration of the choice of operative therapy is dependent on the pathogenesis underlying each case of retinal detachment. **Case presentation:** This case report found complaints of patients with sudden blurred vision without red eyes or calm eye conditions and a diagnosis with regmatogen retinal detachment. From the history, in this patient was obtained, complaints of blurred vision such as closed curtains complained of the patient and complaints were preceded by views such as seeing flashes of light or photopsia and vision such as flying objects or floaters which are the most common complaints in 50% of patients with retinal regmatogen retention. occurs because of the lattice degeneration process. In cases of severe and extensive retinal detachment, the combination procedure for vitrectomy and scleral buckle is the primary choice for optimal outcome. **Conclusion:** At follow-up, posterior segment examination revealed retinal attachments that were uncomplicated. Follow up 2 weeks post therapy found that the retina was attached and had vision with improvement.

1. Introduction

The retina consists of multiple layers of photoreceptor cells and nerve cells that are in the retinal pigment epithelial layer (RPE). RPE is a monolayer cell attached to the Bruch membrane, which is a collagen layer with a thickness of 2-4 μm bordering Corio-capillary which provides nutrients to RPE and part of the retina. Retinal detachment is a condition where there is a separation between the retinal neurosensory layer and RPE. This layer separation occurs in the potential space formed during the retinal embryology of the Optic Cup.^{1,2}

Retinal detachment is divided into three categories. The most common type is regmatogen retinal detachment (rhegmatogenous retinal detachment), which is a result of the process of tearing of the retinal layer. The second category is tractional retinal detachment based on the

occurrence of vitreous attachment to the retina which results in the neurosensory pull of RPE. In certain circumstances a combination of regmatogen and tractional can occur. The third category is exudative retinal detachment related to the inflammatory process, malignancy. In this exudative type there is accumulation of subretinal fluid which ends in the release of the retinal layer.^{1,3}

From epidemiological data in the United States, the incidence of retinal detachment is 12.5 cases per 10,000 per year. About 40-50% of cases are associated with risk factors for myopia, 30- 40% with a history of cataract surgery and 10-20% are ocular trauma. Most cases of trauma occur at the age of children and cases with myopia often occur at the age of 25-40 years.^{3,4}

Reported cases of retinal detachment managed by *Buckle Sclera and cryotherapy*.

2. Case Reports

A man, 43 years old, out of town address, private employee occupation, came to the eye clinic on November 2, 2016. Anamnesis is the main complaint left eye blurred as partially covered by the curtain since, 2 days before entering the hospital. Travel history of the disease since, 2 days ago the patient complained of sudden blurred vision in the left eye. Complaints in without accompanied by red eyes. Sight is felt like a curtain closed on the field of view inside. Patients have never complained of vision that disappears suddenly before, eye pain is absent, complaints of

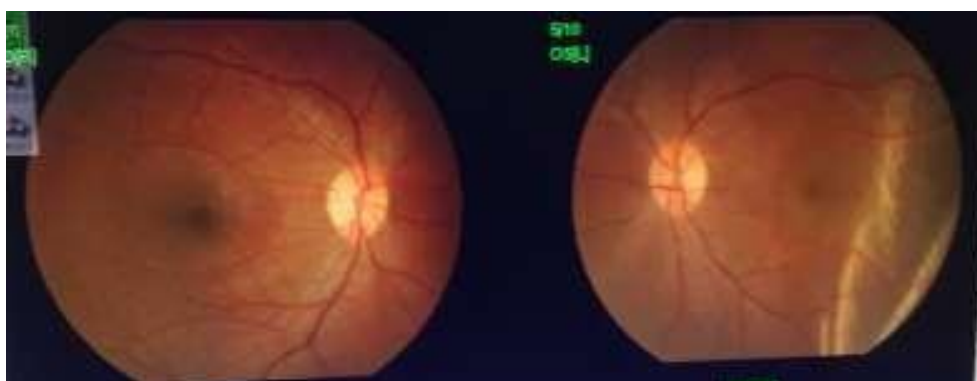
dizziness and headache are absent. The patient then went to a hospital in Muara Enim and said that the left eye nerve was loose. The patient was then referred to a private hospital in Palembang for further treatment. The patient said that since ± 7 days ago complained of the left eye seeing flashes of light and seeing as flying objects that disturbed vision. Past medical history of eyeball trauma is nothing, History of eyeglasses: nothing, History of high blood pressure is nothing, History of diabetes is nothing, Family history of having experienced loose in the eye nerve (-).

Physical examination generalist status General state: Good, Consciousness: composition, Blood Pressure: 120/80 mmHg, pulse: 72x / minute, Temperature: 36.7oC, Respiration: 16 X / minutes.

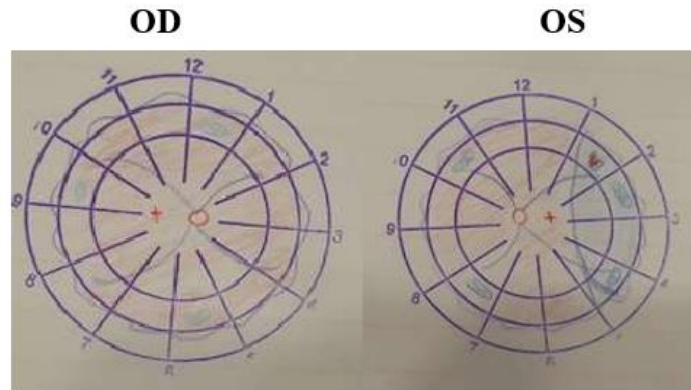
Ophthalmology Status Table

	OD	OS
Vision	6/6	4/60 pH (-)
Intraocular Pressure	15 mmHg	7 mmHg
Eyeball position	Ortoforia	
Eyeball Movement	Good in all directions	Good in all directions
Palpebra	Quiet	Quiet
Conjunctiva	Quiet	Quiet
Cornea	Clear	Clear
Front Eye Chamber	Medium	Medium
Sliced	Good image	Good image
Pupil	Bulat, sentral, RC (+), Ø 3mm	Bulat, sentral, RC (+), Ø 3mm
Lens	Clear	Clear
Posterior Segment	RFOD (+)	RFOS (+)
Papil	Round, firm boundary, red N, c / d 0.3 a / v 2/3	Round, firm boundary, red N, c / d 0.3 a / v 2/3
Macula	RF (+) N	RF (-)
Retina	<i>Lattice degeneration (+)</i> peripheral, good blood vessel contour	<i>Lattice degeneration (+)</i> peripheral, Undulation (+) super-temporal, tear (+) super-temporal

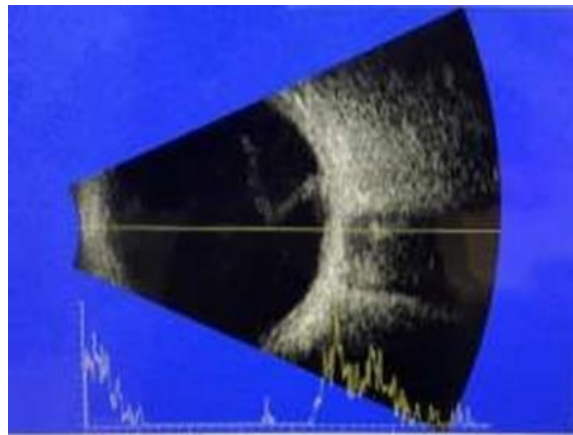
Pre-operative fundus photo



Preoperative retinal drawing image



USG image



Vitreous: echo-free, Retina: Not intact, Visible like lesion membrane attached to the optic nerve, Choroid: not thickened.

The diagnosis is Rhegmatogenous OS Retinal Ablation, Management of Informed Consent, Hospital Entrance, Laboratory Examination, Thorax X-ray Examination, Pro: PDL and Anesthesia counselor, Pro Buckle Sclera + Cryo-retinopexy, Pro Laser photocoagulation OD.

Laboratory results: Hemoglobin: 11 g / dl (14-18 g / dl), Leukocytes: 6,500 / mm³ (5,000- 10,000 / mm³), LEDs: 11 mm / hour (< 29 mm / hour), Glucose during: 101 mg / dl (<110 mg / dl), Ureum: 23 mg / dl (15-39 mg / dl), Creatinine: 0.9 mg / dl (0.9-1.3 mg / dl), Sodium: 145 mmol / l (135-155 mmol / l), Potassium: 3.8 mmol / l (3.5-5.5 mmol / l), Bleeding period: 2 minutes (1-3 minutes), Freezing period: 9 minutes (9 -15 minutes).

Chest X-ray is not found abnormalities in the heart and lungs. Prognosis of Quo ad vitam: Bonam, Quo ad Functionam: Dubia ad bonam.

3. Discussion

This case report found complaints of patients with sudden blurred vision without red eyes or calm eye conditions and a diagnosis with RRD. From epidemiological data in the United States, there was an incidence of retinal detachment of 12.5 cases per 10,000 per year. About 40-50% of cases are associated with risk factors for myopia, 30-40% with a history of cataract surgery and 10-20% are ocular trauma. Based on population-based studies by Haiman et al in Iowa and Minnesota, USA, the RRD incidence is 12 cases per 100,000 population. Whereas from a study in Singapore by Wong et al reported the incidence of RRD was 11.6 cases per 100,000 in the Chinese population, 7 cases per 100,000 in the population in Malaysia, and 3.9 cases per 100,000 in the population in India.^{3,4}

According to Schwartz SG et al. Rhegmatogenous retinal detachment occurs when there is a full-thickness tear in the retina, along with a change in physiological balance that results in retinal neurosensory release from RPE. According to

Shunmugam M et al, the risk factors that make up RRD are myopia, old age, trauma, and lens surgery.¹⁴

According to Burton TC et al in patients with myopia axial lengthening of the eye changes occur in the peripheral retina. The elements of the retina undergo a process of stretching and decreased blood supply, arteries and veins appear more-straight, the retina will experience thinning. The retinal pigment epithelium will thin, the pigments clot and will move to the inner layer of the retina and degenerate lattice. Lattice degeneration is meaningful because it increases the risk of a hole or retinal detachment. These changes usually start from the super-temporal region.¹⁵

In addition, one of the triggers for retinal detachment is trauma. According to Connoli et al. The role of trauma in the occurrence of trauma has been known for a long time, ocular contusions mainly have an important role in retinal detachment, which occurs in 16-18% of cases. All types of trauma such as ocular contusions, penetrating eyeball, and head trauma can cause retinal detachment.¹⁶

From the history, in this patient was obtained, complaints of blurred vision such as closed curtains complained of the patient and complaints were preceded by views such as seeing flashes of light or photopsia and vision such as flying objects or floaters which are the most common complaints in 50% of patients with retinal regmatogen retention. occurs because of the lattice degeneration process.

Shunmugam M, et al explained that Although the initial symptoms of retinal detachment can vary, the common symptom that occurs is usually in the form of flash light seeing flashes due to PVD, seeing flying objects due to increased nfloaters in vitreous due to release of RPE cells and or blood into the cavity vitreous. There is visual defect and decreased visual acuity due to macular involvement. In this patient there was no history of trauma. This needs to be asked because trauma is another predisposing factor that often occurs in regmatogen retinal detachment. A history of refractive abnormalities in patient's needs to be asked to see the possibility of high myopia which can trigger the occurrence of lattice degeneration.¹⁷

Shunmugam M, et al Lattice degeneration is an abnormal condition in the retina that is characterized by discontinuity of the internal limiting membrane accompanied by neurosensory atrophy below. Atrophic neurosensory conditions will cause thinning of the retinal layer to form small holes in the degeneration of the lattice, and become the entrance of vitreous fluid that slowly fills the subretinal space, so that the neurosensory layer is separated from the epithelial layer of the retinal pigment. The longer the more vitreous fluid that accumulates in the subretinal space, so that the ablation that occurs will be more extensive.¹⁷

On examination of the posterior segment, undulation (+) of the superior region and tear can be identified according to Lincoff Rule 1. In accordance with AAO, Lincoff rule 1 is a retinal detachment that occurs in the Super-temporal or Nasal-temporal quadrants. Super-temporal break locations, 98% have the highest undulation.

This patient was diagnosed with OS regmatogen retinal detachment. The patient was treated with operative action Buckle Sclera + Cryo-retinopexy / cryo-therapy. This procedure was chosen because in this patient the retinal detachment that occurs is not complicated and only covers one quadrant and the retinal break can be identified properly. The sclera buckle procedure can be applied in cases of simple retinal detachment like this. According to Schepens CL et al at this time PPV and pneumatic retinopexy management increased in the management of RRD that is not complex, but Scleral Buckle still has an important role in several types of RRD. In some cases, vitreous surgery is needed to release the pull of vitreoretina which cannot be adequately released by scleral buckling. In the experience of expert Scleral buckle is a therapeutic choice with RRD cases that are not difficult, retinal dialysis and RRD that match the round holes. absence of posterior vitreous detachment (PVD), dialysis, round or atropic hole, anterior tears to the equator, tears inferiorly, and cases of detachment of certain retinal nerves with PVR. Scleral Buckle is the treatment of choice for several types of RRD, especially in the eye without posterior vitreous detachment (PVD). The aim is to

create a curve into the eye wall, so that the retinal pigment epithelium approaches the neuroretina around the tear. Sclera indentation is achieved by placing a permanent buckle in the area corresponding to the tear.¹⁸

Custodis E. et al said that the buckle that caused indentation of the sclera reduced the amount of vitreous traction, changed the direction of the traction from vitreous and reduced the vitreous that passes through the tear region to the subretinal space. Only using buckle sclera cannot prevent repeated retinal tears, so cryotherapy is needed to form a permanent adhesion between neuroretina and RPE. Subretinal fluid drainage is one part of the procedure for sclera buckle surgery. Removal of subretinal fluid will make the retina closer to RPE. Drainage with sclerotomy is done after cryotherapy and silicon buckling but before stitching is performed. In addition, trans-scleral cryotherapy can be performed with the aim of making scar in corio retinal so that a strong retinal attachment occurs.¹⁹

The selection of operating procedures in the management of regmatogen retinal detachment is a decision based on the operator's consideration of the evaluation in each case. In cases of severe and extensive retinal detachment, the combination procedure for vitrectomy and scleral buckle is the primary choice for optimal outcome. In addition, the availability of facilities, trained operators and assistants, and consideration of the large operating costs are also noteworthy.

In this patient prognosis with *dubia ad bonam*, according to Duane's ophthalmology, 90% of cases of retinal detachment can be corrected with one operation, and the sooner the surgery is performed the better the prognosis is obtained, but in some cases more than one operation is needed to reattach it detached retina. Besides macular involvement also affects vision after surgery, if the macula is not involved then vision has a very good prognosis. In this patient, no macular involvement was found.

4. Conclusion

Reported cases of regmatoge retinal detachment in patients, namely men aged 43 years. After

anamnesis and ophthalmology examination, there was a suspicion of regmatogen retinal detachment. The risk factor for retinal detachment in these patients is lattice degeneration.

After the diagnosis is made on the patient then determined the appropriate operative action for this patient. In this patient, Buckle sclera and cryotherapy are performed with the consideration that Ablatio that occurs in these patients is not a case of complex ablatio or not too severe and only about one quadrant only.

At follow-up, posterior segment examination revealed retinal attachments that were uncomplicated. Follow up 2 weeks post therapy found that the retina was attached and had vision with improvement. Follow-up can be followed by an ophthalmologist who is close to the patient's domicile.

5. References

1. Liesegang T J. Basic and Clinical Science Course. Section 12. Retina and Vitreous. The foundation of the American Academy of Ophthalmology; 2011-2012.
2. Ryan SJ. Retinal Reattachment: Surgical Principles and Technique. Surgical retina. Retina. Fourth edition. Vol.3. 2005.
3. Regillo CD, Brown GC, Flynn HW. Vitreoretinal Disease; The Essentials. New York- Stuttgart 1999.
4. Peyman GA, Meffert SA, Conway MD. Surgical Techniques for The Treatment of Retinal Tears and Complicated Retinal Detachment. Vitreoretinal Surgical Techniques. Second Edition. New Orleans, LA, USA.2007.
5. Kanski JJ. Clinical Ophthalmology. Seventh edition. Chapter 16. Retinal Detachment; 2011.
6. Williamson TH. Rhegmatogenous Retinal Detachment. Vitreoretinal Surgery. Springer. London 2007.
7. Chou T, Siegel M. The Mechanics of Retinal Detachment. New Jersey Institute of Technology, Newark, NJ, 07102-1982.

8. Lai TYY. Retinal Complications of High Myopia. The Hongkong Medical Diary.2007.
9. Lewkonia,M.S, Davies, J.D.Salmon. British Journal Ophthalmology. Lattice degeneration in a family with retinal detachment and cataract. Sept 1973.
- 10.Lattice degeneration. Conditions and Diseases.
(<http://www.retinalmd.com/en/resources/conditions-and-disease>). Download at 4th December 2016.
- 11.Gout I, Mellington F, Tah V et al. Retinal Detachment-An Updat of the Disease and Its Epidemilogy-A Discussion on Research and Clinical Experience at The Prince Charles Eye Unit, Windsor, England. Oxford University, England.2011.
- 12.Jain P, Nagpal M, Videkar R, Patil A. Evaluation of Possible Risk Factors for Retinal Re- Detachment after Silicone Oil Removal.AIOC 2010.
- 13.Mehdzadeh M, Afarid M, Haghighi MS. Retinal Redetachment after Cataract Surgery in eyes with Previous Skleral Buckling. Journal of Ophthalmic and Vision Research 2011;vol. 6.
- 14.Schwartz SG, Flynn HW. Primary retinal detachment: scleral buckle or pars plana vitrectomy? Curr Opinion Ophthalmol. 20011;17:245-50.
- 15.Burton TC. The influence of refractive error and lattice degeneration on the incidence of retinal detachment. Trans Am Ophthalmol Soc. 1989;87:143-157.
- 16.Connolly BP, Regillo CD. Rhegmatogenous retinal detachment. In: Tansman W, Jaeger EA, eds. Duane's Ophthalmology. 2013 ed. Philadelphia, PA: Lippincott Williams & Wilkins; 2013:vol 3, chap 27.
- 17.Shunmugam M, Shah AN, Hysi PG, Williamson TH. The pattern and distribution of retinal breaks in eyes with rhegmatogenous retinal detachment. Am J Ophthalmol 2014;157:221-226.
- 18.Schepens CL, Okamura ID, Brockhurst RJ. The scleral buckling procedures. Surgical techniques and management. AMA Arch Ophthalmol 1957;58(6):797-811.
- 19.Custodis E. Treatment of retinal detachment by circumscribed diathermal coagulation and by scleral depression in the area of tear caused by imbedding of a plastic implant. Klin Monbl Augenheilkd Augenarztl Fortbild 1956;129(4):476-495.