



Anti-Vascular Endothelial Growth Factor Injection in Wet Age-Related Macular Degeneration

M. Usman Salim^{1*}, AK Ansyori¹, Ramzi Amin¹

¹Department of Ophthalmology, Faculty of Medicine, Universitas Sriwijaya, Indonesia

*correspondence author email: usman.salim@gmail.com

Abstract

Introduction. AMD is a macular progressive degeneration that arises at the age of more than 50 years, which is characterized by the presence of drusen which is a deposit of material between the retinal pigment epithelium (RPE) and the Bruch membrane. The prevalence of AMD is 29.2% unilateral and 70.8% bilateral. In unilateral wet AMD, 50% will develop on the other eye in a period of 5 years.

Case Presentation. A woman, Mrs. S, 59 years old, civil servant working, located in the city, came to the Polyclinic RSMH on January 21, 2019. Anamnesis (Auto-anamnesis) the main complaint of vision of the left eye blurred since, 2 months ago. Since about two months ago, sufferers complained of vision in the left eye blurred, blurred felt suddenly, darker vision in the middle. Since about two weeks ago, sufferers complained that his left eye vision had become blurred. The view in the middle is covered with black shadows and accompanied by waves. Working diagnosis of macular oculi sinistra ec wet age-related macular degeneration. The treatment is informed consent, Pro injection of anti-VEGF intravitreal oculi sinistra, Pro laboratory check, Pro X-ray of thorax PA, Pro consul of internal medicine.

Conclusion. A clinically significant case of macular edema (CSME) has been reported that is treated with intravitreal anti-VEGF combined with focal photon photocoagulation laser. A woman aged 55 years, with complaints of vision both eyes blurred since \pm 6 months ago.

Keywords. anti vascular endothelial growth factor, injection, age-related macular degeneration, wet AMD.

Introduction

Age-related Macular Degeneration (AMD) is a major cause of blindness in developing countries, which causes severe central visual impairment in one or both eyes. AMD is a macular progressive degeneration that arises at the age of more than 50 years, which is characterized by the presence of drusen which is a deposit of material between the retinal pigment epithelium (RPE) and the Bruch membrane. The prevalence of AMD is 29.2% unilateral and 70.8% bilateral. In unilateral wet AMD, 50% will develop on the other eye in a period of 5 years. It is estimated that in 2020 around 8 million people in America have AMD because of an increase in the population of old age¹⁻³

AMD is classified into non-neovascular (*Dry AMD*) and neovascular (*Wet AMD*). Non-neovascular forms are more common and constitute 90% of AMD cases. The neovascular shape is only found in 10% but 85% causes severe visual impairment. Neovascular AMD is characterized by choroidal neovascularization. Risk factors for AMD are old age, hyperopia, bright iris color, family history, smoking, hypertension, hypercholesterolemia and cardiovascular disease.^{1,2,4,5}

In the early stages AMD rarely causes complaints. Complaints are only felt when there have been drusen, choroid neovascularization, the presence of fluid and blood that spreads to the central macula or the movement of blood into the vitreous space, which can cause central visual field disturbances and a sharp decrease in vision that can make sufferers lose independence and the ability for daily activities days.¹⁻³⁻⁵

In 1980-2010, the treatment options for AMD were laser photocoagulation and photodynamic therapy. In early 2010 therapies were introduced using anti-angiogenesis which focused on VEGF inhibition. Therefore, the authors are interested in examining the action of anti-VEGF injection as a treatment for vascular type AMD cases.^{1,5}

Reported cases of wet age-related macular degeneration treated with intravitreal anti vascular endothelial growth factor injection.

Case Report

A woman, Mrs. S, 59 years old, civil servant working, located in the city, came to the Polyclinic RSMH on January 21, 2019 with medical records 761611. Anamnesis (Auto-anamnesis) The main complaint of vision of the left eye blurred since, 2 months ago. Since about two months ago, sufferers complained of vision in the left eye blurred, blurred felt suddenly, darker vision in the middle. Sufferers do not complain to see like lightning, and like a curtain. Red eye complaints and no pain. Patients go to a GP clinic and get two kinds of eye drops, but the patient

forgets the name of the medicine. Complaints are not-reduced, the patient does not seek treatment again.

Since about two weeks ago, sufferers complained that his left eye vision had become blurred. The view in the middle is covered with black shadows and accompanied by waves. Sufferers do not complain of vision like seeing lightning, like being covered by a curtain, and like smoking. Patients seek treatment at RSUD and are referred to RSMH.

Past history of disease History of diabetes is denied, history of high blood pressure is denied, history of heart disease is denied, history of hypercholesterolemia (+) since 2 years ago, history of wearing glasses there, reading glasses, history of trauma to the area around the eye previously denied, history of the same disease in family denied, smoking history denied.

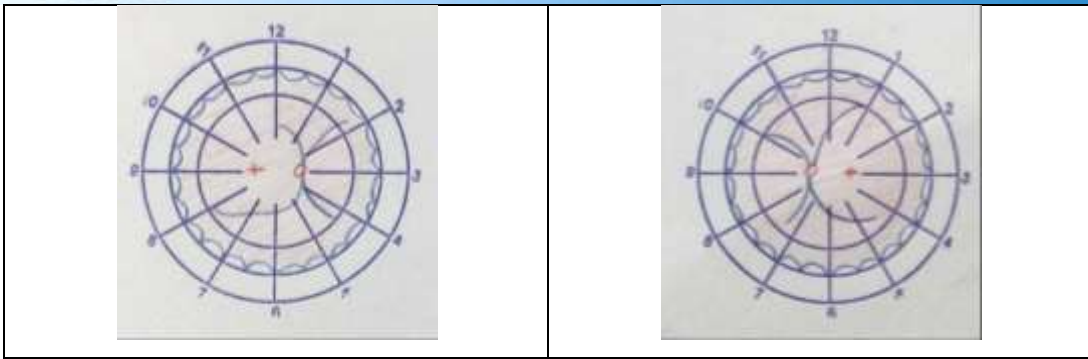
Physical examination generalist status General state: Good, Awareness: Compost mentis, Blood Pressure: 120/80 mmHg, Pulse: 82 x / minute, Respiration: 20 x / minute, Temperature: 36.6 ° C.

Ophthalmologic Status Table (21 January 2019):



	OD	OS
Vision	6/6	4/60
TIO	15,6 mmHg	15,6 mmHg
KBM	Ortoforia	
GBM	good in all directions	good in all directions
Palpebra	Quiet	Quiet
Conjunctiva	Quiet	Quiet
Cornea	Transparent	Transparent
BMD	Medium	Medium
Iris	Good image	Good image
Pupil	Round, central, RC (+), Ø 3 mm	Round, central, RC (+), Ø 3 mm
Lens	Transparent	Transparent
Posterior Segment	RFOD (+)	RFOS (+)
Papils	Round, firm boundary, normal red color, c / d: 0.3, a / v: 2/3	Round, firm boundary, normal red color, c / d: 0.3, a / v: 2/3
Macula	Fovea reflex (+) N	Fovea reflexes (+) are decreased, edema (+)
Retina	Good blood vessel contour	Good blood vessel contour

Retinal Drawing Photos



OD	OS



Fundus photo supporting examination

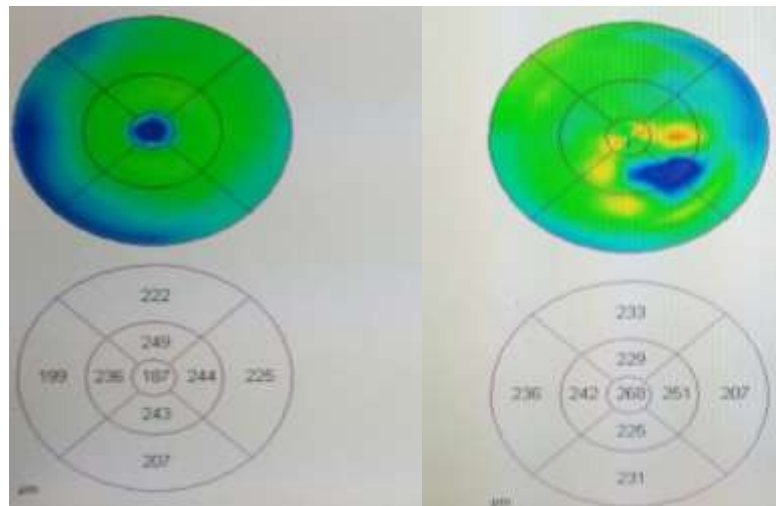
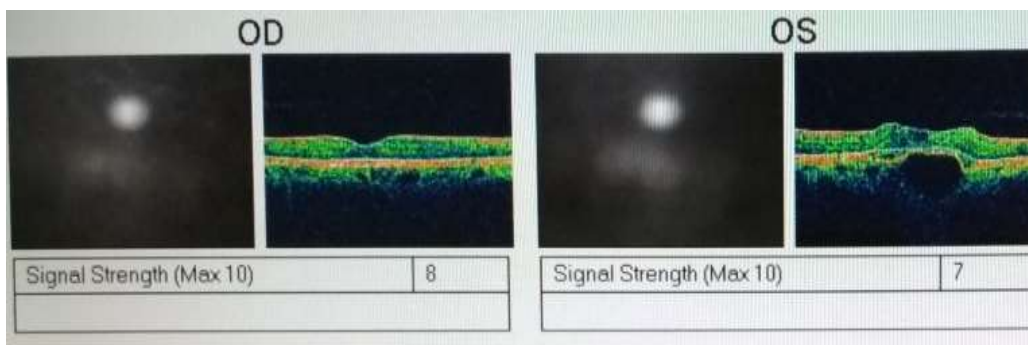
OD	OS
	
<ul style="list-style-type: none"> • Papil: Round, firm boundary, normal red color, c / d: 0.3, a / v: 2/3 • Macula: Fovea (+) reflex N • Retina: Contour of good blood vessels 	<ul style="list-style-type: none"> • Papil: Round, firm boundary, normal red color, c / d: 0.3, a / v: 2/3 • Macula: Fovea (+) reflexes are decreased, edema (+) • Retina: Contour of good blood vessels

Ultrasound Photographs (January 21, 2019)

OD	OS
	

<ul style="list-style-type: none"> • Retina: intact • Vitreus: echofree • Choroid: does not thicken 	<ul style="list-style-type: none"> • Retina: intact • Vitreus: echofree • Choroid: does not thicken
--	--

Photo Optical Coherence Tomography



OD: Visible areas of hyper-reflectivity among hypo-reflectivity areas, Macular depression (+). OS: Visible hypo-reflectivity areas under RPE, RPE detachment (+), macular depression disappears. The Amsler Grid test is OD: Central vision or macular function is still normal OS: Central vision defect (+), metamorphopsia (+). The differential diagnosis is macular oculi sinistra edema wet age-related macular degeneration of the ocular sinistra, macular edema oculi sinistra ec polypoidal choroidal oculi vasculopathy of the ulcers, macular edema oculi sinistra ec diabetic

macular edema of the ocular sinistra. Working diagnosis of macular oculi sinistra ec wet age-related macular degeneration. The treatment is informed consent, Pro injection of anti-VEGF intravitreal oculi sinistra, Pro laboratory check, Pro X-ray of thorax PA, Pro consul of internal medicine. Prognosis is Quo ad vitam: Bonam, Quo ad Functionam : Dubia ad bonam, Quo ad sanationam: Dubia ad bonam.

Discussion

Age-related macular degeneration (AMD) is a macular progressive degeneration that arises at the age of more than 50 years, causing central vision problems. Approximately 10-15% of AMD is neovascular AMD which is characterized by choroid neovascularization which can cause severe visual impairment.¹⁻³

In this case report, a 59-year-old woman with a chief complaint of central vision in the left eye blurred. Old age is one of the risk factors for suffering from AMD. Studies show AMD as a major cause of the sharp decline in central vision in one or both eyes in people aged over 50 years in the United States. the risk of AMD is 11% higher at the age of 64-74 years. 3,5 Patients have a history of hypercholesterolemia two years ago. Research shows that neovascular AMD is closely related to high cholesterol levels.^{3,5,8}

Patients complain of blurred left eye vision is felt by patients since more or less two months ago, blurred felt suddenly, darker vision in the middle. Patients seek treatment at the local hospital but the complaint does not decrease, the patient does not seek treatment again. Since about two weeks ago, sufferers complained that his left eye vision had become blurred. The view in the middle is covered with a black shadow and the object seen by the patient appears crooked. Patients seek treatment at the local hospital, and are referred to RSMH. Based on studies, AMD in the initial fae very rarely causes complaints. Complaints are only felt when there has been a drusen in the central macula or choroid neovascularization which causes central visual field disturbances and a sharp decrease in vision.^{1,2,9-11}

On ophthalmological examination, 6/6 right eye vision and 4/60 left eye vision cannot be corrected with a pinhole, with no abnormal anterior segment seen. On examination of the posterior segment of the left eye, the fovea reflex in the macula decreases accompanied by a picture of soft drusen around the macular area. Simple and accurate examination to determine the existence of

macular dysfunction, namely check Amsler grid. On Amsler grid examination found a central vision defect and distortion (metamorphopsia) which is a sign of neovascularization in the macula area, which is an emergency.^{2,3,10,12} These findings correlate with the results of the OCT examination and found a description of the OCT. the thickening of the Bruch layer is accompanied by elevation of rPe and visible accumulation of subretinal fluid. This is due to the presence of choroid neovascularization which is the growth of new blood vessels from choriocapillary that extend into the subretinal cavity through defects in the Bruch membrane, resulting in leakage of fluid and blood. Blood can be absorbed, spread below the retina, or move to the vitreous to become vitreous bleeding.^{1,2,9-11}

Investigations which are the gold standard to determine choroid neo-vascularization are Fundus Fluorescein Angiography (FFA) which can determine the type of lesion, size and location of choroid neovascularization, so that further action can be planned.^{2,3,10,12} In patients showing leakage in the final phase which shows leaks in the choriocapillary, and appears irregular hyperfluorescent in the vicinity without pooling which shows RPE detachment.

Based on history and examination, the differential diagnosis of this patient is macular edema ec wet age-related macular degeneration, polypoidal choroidal vasculopathy, and diabetic macular edema. Age-related macular degeneration is macular degeneration that occurs in old age, more than 50 years. The prevalence of AMD is 29.2% unilateral and 70.8% bilateral. In unilateral wet AMD, 50% will develop on the other eye in a period of 5 years.¹⁻³

Polypoidal choroidal vasculopathy is a retinal disease involving choroidal blood vessels characterized by the presence of polypoidal aneurysms with or without branching of blood vessel tissue. Usually occurs in middle age. The prevalence of AMD is 10% unilateral and 90% bilateral. Vision is better than AMD-associated CNV. This patient is classified as old age with poor vision, and the prevalence of unilateral polypoidal choroidal vasculopathy is low, only 10%, so the differential diagnosis of polypoidal choroidal vasculopathy can be ruled out.

Diabetic retinopathy is a progressive disease that damages the integrity of retinal blood vessels. Proliferative diabetic retinopathy is characterized by neovascularization, pre-retina bleeding, and vitreous bleeding. The incidence of diabetic retinopathy in patients with diabetes mellitus type II non-insulin dependent is 34% in 4 years. The progression to PDR in 4 years was 2.3%. An average HbA1c level of 7.0-7.9% for 1 year can cause diabetic retinopathy as much as 14.3% .^{2,19,20} Although on fundusoscopic examination and OCT on diabetic macular edema can resemble the picture of AMD, but from anamnesis it is known that this patient does not have

diabetes mellitus and has been confirmed through laboratory tests that show blood sugar results within normal limits.

Diabetic retinopathy is a progressive disease that damages the integrity of the blood vessels of the retina. Proliferative diabetic retinopathy is characterized by neovascularization, pre-retina bleeding, and vitreous bleeding. The incidence of diabetic retinopathy in patients with diabetes mellitus type II non-insulin dependent is 34% in 4 years. The progression to PDR in 4 years was 2.3%. An average HbA1c level of 7.0-7.9% for 1 year can cause diabetic retinopathy as much as 14.3% .2,19,20 Although on fundusoscopic examination and OCT on diabetic macular edema can resemble the picture of AMD, but from the history it is known that this patient does not have diabetes mellitus and has been confirmed through laboratory tests that show blood sugar results within normal limits. Anti-VEGF injection in this patient was chosen as therapy because it can inhibit VEGF so that CNV becomes regression and also prevents the formation of new CNV. Can be used primarily or additionally during laser therapy. Currently intravitreal anti-VEGF that are developing are ranibizumab, pegabtanib sodium, and bevacizumab, which can stabilize vision or temporarily improve vision. ^{1-3,13-15}

At the first day of follow-up after injection the vision was 5/60, on the seventh day 6/60 was obtained. This shows a good response to the therapy given. According to the guidelines for handling wet AMD in Indonesia issued by PERDAMI anti VEGF, it is given once every month in the first 3 months, after which it is given pro-renata. Patients were given a second anti-VEGF injection in the left eye and had vision improvement being 6/30 on day VII after the second injection. Patients were planned for a third anti VEGF injection in the third month of therapy and continued according to the anti VEGF injection protocol in wet AMD.

The prognosis of quo ad function is dubia ad bonam, because there is improvement in vision after anti-VEGF injection, and there are no contra indications (fluorescent allergies) to continue therapy. The prognosis of quo ad Sanationam dubia ad bonam depends on the patient's compliance with re-control and adopting therapeutic protocols. While the prognosis of quo ad vitam is bonam. ^{1-3,5}

Conclusion

A clinically significant case of macular edema (CSME) has been reported that is treated with intravitreal anti-VEGF combined with focal photon photocoagulation laser. A woman aged 55 years, with complaints of vision both eyes blurred since \pm 6 months ago. When you go to the eye clinic for blood sugar levels when, blood pressure and blood cholesterol levels increase. From

the results of fundoscopic examination, thickening of the retina and hard exudates within 500 μm from the central macula in the right and left eye was in accordance with CSME criteria.

The treatment chosen for this patient was intravitreal anti-VEGF (bevacizumab) injection in the right and left eye every month for 3 months. One week later, the focal photocoagulation laser was performed on the right and left eyes. The patient's final vision 1 week after the focal photocoagulation argon laser was performed showed improvement. The initial vision of the right and left eye 3/60 becomes 6/30. Blood pressure, blood sugar levels, and cholesterol at follow-up are always controlled, so they can help reduce the risk of progressive retinopathy, macular edema and decreased vision.

References

1. Ying Gui-Shuang. Age Related Macular Degeneration - The Recent Advances in Basic Research and Clinical Care. Croatia: In Tech. 2012; 3-99.
2. American Academy of Ophthalmology Staff. Retina and Vitreous. Italy: American Academy of Ophthalmology. 2014; 55-89, 345-368.
3. Houde Susan Crocker. Vision Loss in Older Adults: Nursing Assessment and Care Management. New York: Springer Publishing Company. 2007; 15-22.
4. Maguire JI, et al. Will's Eye Institute 5-Minutes Ophthalmology Consult. Philadelphia: Lippincot. 2012. 60-1, 76-7, 162-3.
5. Penfold, Philip L. Macular Degeneration. New York: Springer. 2005; 23-191.
6. Porte Clare. Pathogenesis and Management of Age-Related Macular Degeneration. In Scottish Universities Medical Journal. 2012;141-153.
7. Hollyfield Joe G, et al. Retinal Degenerative Diseases. New York: Springer Publishing Company. 2014; 193-330.
8. Holz FG, Spaide RF. Medical Retina. New York: Springer. 2005; 95-140, 165-176.
9. Schick Tina, et al. Genetics of Unilateral and Bilateral Age Related Macular Degeneration Severity Stages. In Plos One Journal June 2016; 1-11.
10. Khurana AK. Comprehensive Ophthalmology 4th ed. New Delhi: New Age International Ltd. 2007; 249-86.
11. Holz FG, Spaide RF. Medical Retina. New York: Springer. 2007; 1-24.

12. Liu Gangjun. Topics in Optical Coherence Tomography. Croatia: InTech. 2012; 1-104, 197-237.
13. Coscas Gabriel, et al. Optical Coherence Tomography in Age-Related Macular Degeneration. Heidelberg: Springer. 2009; 183-274.
14. Wong RL, Lai TY. Polypoidal Choroidal Vasculopathy: An Update on Therapeutic Approaches. In J Ophthalmic Vis Res 2013; 8 (4): 359-37.
15. Kirchhof B, Wong D. Vitreo-retinal Surgery. Berlin: Springer. 2007; 1-98.
16. Tombran, Joyce. Visual Prosthesis and Ophthalmic Devices, New Hope in Sight. New Jersey: Humana Press. 2007; 251-8.
17. Mohamed S, Timothy YY. Intraocular Gas in Vitreoretinal Surgery. In HKJ Ophthalmol Vol14 No1.2014; 8-13.
18. Kontos Andreas, et al. Retinal Disorder -Duration of Intraocular Gases Following Vitreoretinal Surgery. Berlin: Springer-Verlag. 2016; 1-6.
19. International Council of Ophthalmology. ICO Guidelines for Diabetic Eye Care. 2017; 1-34.
20. Romero Aroca P, et al. Differences in Incidence of Diabetic Retinopathy Between Type 1 and 2 Diabetes Mellitus: A Nine-Year Follow-up Study. In Br J Ophthalmol 2017;0: 1–6.