



# Sriwijaya Journal of Ophthalmology

Journal Homepage: <https://sriwijayaophthalmology.com/index.php/sjo>

## Diagnosis and Management of Central Serous Chorioretinopathy

Ammar Fardhana<sup>1\*</sup>, AK Ansyori<sup>1</sup>, Ramzi Amin<sup>1</sup>

<sup>1</sup>Department of Ophthalmology, Faculty of Medicine, Universitas Sriwijaya, Palembang, Indonesia

### ARTICLE INFO

#### Keywords:

Diagnosis  
Central serous chorioretinopathy

#### Corresponding author:

Faneisha

E-mail address:

[ammар.fardhana@gmail.com](mailto:ammар.fardhana@gmail.com)

All authors have reviewed and approved the final version of the manuscript.

<https://doi.org/10.37275/sjo.v3i1.12>

### ABSTRACT

**Introduction:** Abnormalities in the macula is a very significant disorder. One abnormality that can be found is central serous chorioretinopathy (CSC). This case report aims to explain the diagnosis and management of Central Serous Chorioretinopathy. **Case presentation:** A 32-year-old man, a soldier, came for treatment at hospital on May 2017. Anamnesis of major complaints right eye blurred since, 1 week before hospitalization. From the investigations, in the right eye, the armsler grid examination showed an impression of metamorphopsia. On examination of the fundus photo, an impression of macular area edema with a clear border is obtained. OCT examination revealed that there was elevation of neuroretina tissue in the macula. This patient was managed by laser photocoagulation at the point of leakage of subretinal fluid. **Conclusion:** The diagnosis of central serous chorioretinopathy is made through history taking, ophthalmological examination, and supporting examinations of armsler grid, photo fundus, OCT and FFA. Laser photocoagulation can be performed, especially in cases of persistent, chronic, recurrent, or occupational needs.

## 1. Introduction

The macula is the part of the eye that is responsible for detailed vision / requires focus and is very much needed to perform daily activities as a functional human being, for example reading or driving. Therefore, abnormalities in the macula is a very significant disorder.<sup>1,2</sup>

One abnormality that can be found is central serous chorioretinopathy (CSC) / central serous retinopathy (CSR) / idiopathic central serous chorioretinopathy (ICSC). This disorder is defined as elevation of the sensory retinal pars due to serous fluid in the macular region, with an idiopathic etiology.<sup>3,4</sup>

Epidemiologically, this disease is generally found to be six times more in men with an incidence of 10 per 100,000 population, white race, Asian and Hispanic, and productive age (25 - 55 years), with factors predisposing to stress and corticosteroid use. In this case, productivity is one of the vital components of human function.

Considering that 83% of sensory input comes from the organ of vision, abnormalities in the macula that can sufficiently interfere with this function should be handled properly by health practitioners.<sup>3,4</sup> This case report aims to explain the diagnosis and management of Central Serous Chorioretinopathy.

## 2. Case Reports

A 32-year-old man, address in the city, military occupation, came for treatment at the eye clinic of General Hospital Dr. Mohammad Hoesin on May 23, 2017 with No. Medical Record 970363. Anamnesis of major complaints Right eye blurred since, 1 week before hospitalization.

The history of the disease is since, 1 week ago sufferers complain of blurred right eye. Blurring is felt suddenly, complaints seeing straight lines look crooked (+), visions such as being covered with black shadows (-), complaints seeing like flashes of

light (-), complaints seeing objects appear smaller (-), red eyes (-), eye dirt (-), pain (-). The patient then goes to an ophthalmologist and is referred to Mohammad Hoesin Hospital.



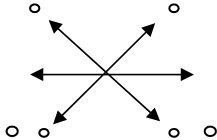
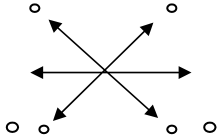
Past medical history is a history of denial of trauma to the eye, history of the same complaints before (-), history of drug consumption (-), history of diabetes (-), history of high blood pressure (-), history of glasses (-).

Work history is a daily sufferer who works as a TNI. In the last 3 months the patient attended education as a condition of promotion. Sufferers admit that lately they have a lot of things that are

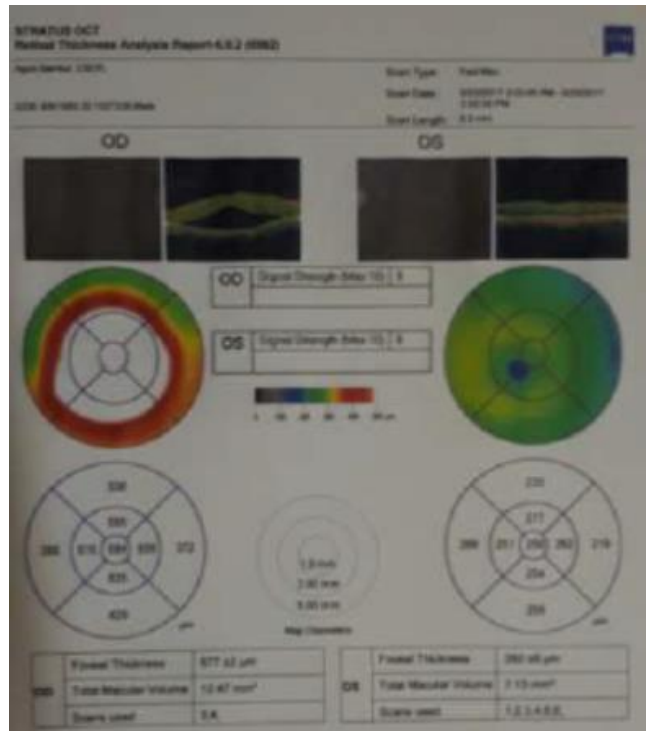
being thought about and worrying about. As a person, the patient claims to have a high and ambitious competitive spirit.

Physical examination generalist status General state: Appear mild pain, Awareness: compost mentis, Blood pressure: 110/80 mmHg, Pulse frequency: 80 x / minute, Breath frequency: 20 x / minute, Temperature: 36.50C, Head: Normal, Eyes (see ophthalmologic status), Neck: No enlargement of the KGB, Pulmo: Within normal limits, Heart: Normal heart sounds, Abdomen: Within normal limits, Extremities: Within normal limits.

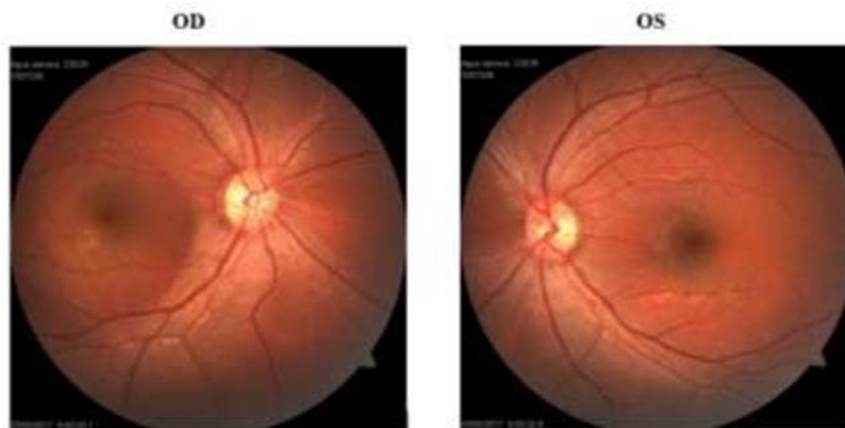
Ophthalmology Status Table

	Right Eye	Left Eye
		
Vision	6/15 ph (-)	6/6
Intra Ocular Pressure	15,6 mmHg	15,6 mmHg
Eyeball Position	Ortoforia	
Eyeball Movement		
Palpebra	Quiet	Quiet
Conjunctiva	Quiet	Quiet
Cornea	Clear	Clear
Front eye chamber	Medium	Medium
Sliced	Good image	Good image
Pupil	B, C, RC (+), Ø 3 mm	B, C, RC (+), Ø 3 mm
Lens	Clear	Clear
Posterior Segment RFODS	(+)	(+)
FODS	Papil: Round, firm boundary, normal red color, c / d 0.3, a / v 2: 3 Macula: RF (+) □, edema (+) Retina: Contour of vessels good blood	Papil: Round, firm boundary, normal red color, c / d 0.3, a / v 2: 3 Macula: RF (+) N Retina: Contour of vessels good blood

Supporting examination of OCT results



Impression of retinal neurosensory elevation in the macular region Image of fundus photo



OD impression Edema of macula area with firm boundaries

Laboratory results table

Examination test	Value	Normal
Hemoglobin	13,4 g/dL	13,2 - 17,3 g/dl
Hematocrit	40%	43 - 49 %
Leukocytes	6900/mm <sup>3</sup>	4500 - 11000/mm <sup>3</sup>
Platelets	232.000/µL	150000 - 450000/ µL
Count type	0/3/60/26/11	1/6/50/20/8
Bleeding time	2 minutes	1 - 3 minutes
Freezing time	9 minutes	9 - 15 minutes
BSS	107 mg/dl	< 200 mg/dl
Ureum	22 mg/dl	16,6 - 48,5 mg/dl
Creatinine	0,89 mg/dl	0,50 - 0,90 mg/dl

Management is informed consent, Pro complete blood laboratory check, Pro Fundus Fluorescein Angiography examination. Prognosis of Quo ad vitam: Dubia ad bonam, Quo ad functionam: Dubia ad bonam.

### 3. Discussion

In this case report reported a 32-year-old man came to the eye clinic of Dr. Mohammad Hoesin General Hospital Palembang with complaints of blurring right eye since, 1 week ago.

From the history it was found that 1 week ago the patient complained of blurring in his right eye, blurring was felt suddenly. Complaints seeing straight lines appear crooked (+), visions such as being covered by black shadows (-), seeing as flashes of light (-), seeing smaller objects (-), complaints of red eyes (-), eye dirt (-), pain (-). The patient then goes to an ophthalmologist and is referred to Mohammad Hoesin Hospital.

From ophthalmological examination obtained vision in the right eye 6/15 ph (-) and the left eye 6/6. Intraocular pressure of both eyes 15.6 mmHg. In the anterior segment both eyes are within normal limits. Whereas in the posterior segment of the right eye the fovea reflex is decreased.

From the investigations, in the right eye, the armsler grid examination showed an impression of metamorphopsia. On examination of the fundus photo, an impression of macular area edema with a clear border is obtained. OCT examination revealed that there was elevation of neuroretina tissue in the macula.

From the FFA examination the right eye found a chime-stack pattern. This pattern starts with a hyper fluorescence at the point of leakage, then runs vertically and finally laterally resembles a chimney.

From the history and ophthalmology examination and supported by this investigation we diagnose patients with Central Serous Chorioretinopathy OD.

In these patients, the presence of blurred complaints in the right eye, complaints of seeing straight lines appear crooked, and the discovery of decreased fundus reflexes on the examination of the posterior segment shows abnormalities in the

macula. This is reinforced by the results of supporting examinations (armsler grid, photo fundus, OCT, and FFA), with the impression of elevation of neuro retinal tissue in the right eye macular area due to leakage in RPE. On FFA examination, it can be excluded the differential diagnosis of idiopathic polypoidal choroidal vasculopathy as a cause of accumulation of subretinal fluid, where a relatively large source of leakage and polypoid is not found.

Central serous chorioretinopathy is an idiopathic retinal disorder characterized by serous detachment elevation in the sensory layer of the retina in the macula.

This patient is managed by laser photocoagulation at the point of leakage of subretinal fluid. This action is an indication in this case, because the patient needs rapid improvement in vision for his work.

The prognosis in this patient is quo ad vitam and quo ad functionam is dubia ad bonam. Central serous chorioretinopathy is a self-limited disease in which most cases only require observation and resorption of subretinal fluid can occur 3-4 months. Vision improvement is usually directly proportional, but can reach 1 year. While the prognosis of quo ad sanationam is dubia because the recurrence rate of this disease is quite high, reaching 40-50%.

### 4. Conclusion

A case of central serous chorioretinopathy was reported in a 32-year-old male. The patient was treated with laser photocoagulation in his right eye.

The sharp decrease in vision in this case is a result of serous detachment of the retinal sensory in the macular area.

The diagnosis of central serous chorioretinopathy is made through history taking, ophthalmological examination, and supporting examinations of armsler grid, photo fundus, OCT and FFA. Laser photocoagulation can be performed, especially in cases of persistent, chronic, recurrent, or occupational needs.

The prognosis of CSC in general is good, except in chronic, recurrent, and in CSC bullosa cases.

## 5. References

1. Mathews, D.E. Clinical grand rounds. Idiopathic central serous chorioretinopathy. *Optometry Clinics* 1996; 5(1): 175-184.
2. American Academy of Ophthalmology. 2014-2015: *Retina and Vitreous*. Italy: 2014.
3. Kanski JJ. *Clinical Ophthalmology: A Systematic Approach*. 7th ed; Philadelphia: Saunders Elsevier. 2011.
4. Theng K, Roy H. Central Serous Chorioretinopathy. Available from: [emedicine.medscape.com/article/1227025](http://emedicine.medscape.com/article/1227025).
5. American Academy of Ophthalmology. 2014-2015: *Fundamentals and Principles of Ophthalmology*. Italy: 2014.
6. Khurana AK. *Comprehensive ophthalmology*. 4th ed. New Delhi: New Age International; 2007.
7. Vaughan D, Asbury T, Riordan-Eva P, Whitcher J. *Vaughan & Ashbury's general ophthalmology* -17th ed. New York: McGraw-Hill. 2008.
8. Agarwal A. *Fundus Fluorescein and Indocyanine Green Angiography*. Thorofare: SLACK Inc; 2008.
9. Prajna, NV. *FAQs in Ophthalmology*. New Delhi: Jaypee. 2013.
10. Ryan SJ. *Retina*. Fourth Edition. Volume I. Mosby Elsevier. 2006.
11. Jackson, Timothy L. *Moorfields Manual of Ophthalmology*. Elsevier Limited. China: 2008.
12. Yanoff. *Ophthalmology*, 2nd ed. Mosby Inc. Spain: 2004.
13. Shah SP, Desai CK, Desai MK, Dikshit Rk. Steroid-induced Central Serous Retinopathy. *Indian J Pharmacol*. 2011 Sep-Oct; 43(5): 607-8.
14. Tsai, James C. *Oxford American Handbook of Ophthalmology*. Oxford University Press, Inc. China: 2011.
15. Lee ann, Remington. *Clinical Anatomy of Visual System*. Second Edition. Elsevier. USA: 2015.
16. Prakash G, et al. Central Serous Chorioretinopathy: A Review of The Literature. *Eye*. 2013. 2:104-110.