

Pharmacokinetics of Povidone-Iodine and Its Effects on Bacterial Keratitis

Rezandi Aziztama^{1*}

¹Department of Ophthalmology, Faculty of Medicine, Universitas Sriwijaya University/Dr. Mohammad Hoesin General Hospital, Palembang, Indonesia

*Correspondence author email: rezandiaziztama08@yahoo.com

Abstract

The purpose of this study was to investigate the pharmacokinetics and safety of povidone-iodine and its efficacy against bacterial keratitis. The method in phase I, forty New Zealand white rabbits were divided into groups I and II and received intravitreal 0.1% and 0.3% PVI, respectively. Electroretinography (ERG) and histologic examinations were conducted at baseline, 6, and 12 hours. Half-life was determined using high-performance liquid chromatography. In phase II, after the induction of *S. epidermidis*, 0.1% and 0.3% PVI were injected intravitreally once in groups A and B and three times every second day in groups C and D (n 10 in each group). Electroretinographs, histologic examinations, and vitreous cultures were conducted on day 14. Electroretinography and histologic examinations did not reveal any notable retinal damage in phase I in either group. Half-lives were 3.27 and 3.58 hours in groups I and II, respectively. In phase II, all groups demonstrated marked improvement, compared to controls. Bacterial growth was found in four eyes in group A (20, 60, 60, and 70 colony forming units [CFU]) and in three eyes in group B (20, 40, and 60 CFU) but not in those belonging to groups C and D at day 14. Retinal damage with lymphocyte infiltration in the inner retinal layers was more common in groups A and B than in groups C and D. Half-life of PVI was approximately 3 hours in the vitreous. Repeated injection of intraocular PVI, even at low concentrations, is most likely to be effective for the treatment of bacterial endophthalmitis.

Keyword. Povidone-iodine, bacterial keratitis, pharmacokinetics

Introduction

Bacterial keratitis is an important cause of blindness in the developing world, where a number of factors, including malnutrition with vitamin A deficiency, substantially increase the risk of corneal infection. In India, for example, corneal disease, much of which is infectious keratitis, is 1 of the top 10 causes of visual impairment, regardless of sex, age, or socioeconomic factors for antimicrobial agents to reduce the burden of infectious keratitis in resource-poor areas of the world, they must meet certain criteria, including effectiveness against a broad spectrum of organisms, a favorable safety profile, ease of preparation, and minimal expense. Studies suggest that povidone-iodine meets these criteria.^{1,2}

With rare exception, it is effective against all bacteria, viruses, and fungi in vitro, given sufficient contact time; true bacterial resistance to povidone-iodine probably does not exist. The excellent efficacy and broad spectrum activity of PVI against microbial infections has generated interest in its possible intraocular use. These previous studies did not investigate the pharmacokinetics of intraocular PVI. The aim of this study was to evaluate the pharmacokinetics of PVI in vitreous humor and its effect on *S. epidermidis* in rabbit eyes, using single and repeated injections and PVI efficacy for bacterial keratitis treatment.³

Methods

Eighty New Zealand white rabbits (Covance, Princeton, NJ, USA), each weighing approximately 2 kg, were used. All procedures were performed in accordance with Association for Research in Vision and Ophthalmology Statement for the Use of Animals in Ophthalmic and Vision Research. The study was approved by the Pusan National University Yangsan Hospital institutional review board. This study consisted of two phases as follows: Phase I was conducted to elucidate the pharmacokinetics and safety of PVI in the eye, whereas phase II was conducted to determine the efficacy of intravitreal PVI in the treatment of *S. epidermidis* endophthalmitis. Animals with media opacity that obscured fundoscopic examination or ocular disease were excluded at baseline.

Phase I study, forty rabbits were divided into two groups (n 20 in each group). Group I included rabbits receiving intravitreal 0.1% PVI (0.1 mg/0.1 mL) injections, whereas group II rabbits received 0.3% PVI (0.3 mg/0.1 mL) injections. Povidone-iodine was intravitreally injected into the right eye. All eyes underwent slit-lamp and indirect fundoscopic examinations at baseline, and then 0.5, 1, 2, 6, and 12 hours after PVI injection. At each time point, three rabbits were killed and their

vitreous humors were collected after examination. Povidone-iodine concentration in the vitreous humor was calculated using high-performance liquid chromatography (HPLC). Pharmacokinetic analysis of ocular drug concentration-time data was performed using noncompartmental and compartmental analyses. At baseline, 6, and 12 hours after PVI injection, electroretinography (ERG) was conducted in five rabbits in each group.

Phase II study, forty rabbits were divided into four groups (n 10 in each group). All rabbits received 50 colony-forming units (CFU) of *S. epidermidis* intravitreally in both eyes. When signs of endophthalmitis or keratitis were observed, PVI was administered in the vitreous cavity after vitreous aspiration. Group A received a single injection of 0.1% PVI and group B a single injection of 0.3% PVI. Groups C and D received intravitreal 0.1% and 0.3% PVI, respectively, 3 times every second day. Fellow eyes receiving sham injection were controls. Slit lamp and fundoscopic examinations were performed daily during the first week and every other day in the second week. Electroretinography, histologic examination, and vitreous cultures for *S. epidermidis* were conducted at day 14.

In a risk factor analysis using Cox proportional hazards models, we investigated the effect of the following host and disease factors on the primary outcome measure (status of presumed cure): sex, age, laterality, visual acuity, gram stain characteristic, ulcer size, ulcer depth, and inflammation score. Those factors that were significantly associated with the primary outcome variable in univariable comparisons were then included in multivariable regressions to determine the influence of those factors on the relationship between povidone-iodine and presumed cure, and to determine the independence of each factor's effect. Subgroup analyses were also performed in which the relationship between povidone-iodine and presumed cure was determined for study participants grouped on the basis of ulcer size. Hazard ratios >1 favored treatment with povidone-iodine.

Pharmacokinetic analysis of ocular drug concentration-time data was performed using noncompartmental and compartmental analysis (WinNonlin version 3.1 software; Pharsight, Mountain View, CA, USA). Noncompartmental analysis was performed to calculate the following pharmacokinetic parameters: total area under the plasma concentration-time curve from time zero to time infinity (AUC), time-averaged total body clearance (CL), apparent volume of distribution at a steady state (V_{ss}), and terminal half-life ($t_{1/2}$). Compartmental analysis was performed to estimate the compartmental volume of distribution (V_d), maximal elimination rate (V_{max}), and Michaelis-Menten constant (K_m) by fitting the data to the equation that describes a one-compartment model with Michaelis-Menten elimination kinetics.

Electroretinography (ERG) responses were recorded using a commercial ERG system (Verice Science version 6.0 EDI; Electro-Diagnostic, Inc., Redwood City, CA, USA). Rabbits were placed in a dark room for 1 hour. Pupils were dilated by instillation of 2.5% phenylephrine and 1% cyclopentolate hydrochloride. Reference and ground electrodes were placed and clipped on the lateral canthus and the earlobe, respectively, after being shaved. Active electrodes (ERG Jet; Fabrial SA, La Chaux-de-Fonds, Switzerland) were placed on the cornea with Hypro-mellose (Hycell solution, 2%; Samil Pharm., Seoul, Korea), and the head was positioned in the Ganzfeld dome. Dark-adapted ERG responses were recorded by stimulation with 25 to 0 dB white flashes (increasing by 5 dB; 0.0095–3.004 cd-s/m²). Signals were amplified with a bandpass of 1 to 300 Hz. A decrease in postinjection response over 25% was considered significant.

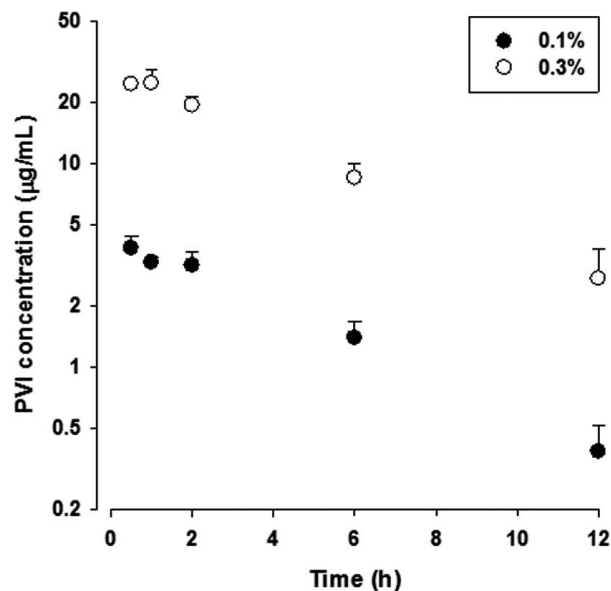


Figure 1. Mean concentration-time profiles of groups I (eyes receiving 0.1% PVI) and II (eyes receiving 0.3% PVI) in the vitreous of rabbits. After intravitreal PVI injection, the mean PVI concentration decreased with a nonlinear decay pattern in both groups, and then it changed to 1-exponential linear decay after 2 hours. *Vertical bars* represent standard deviations.

Results

Clinical Examination. Drug-induced ocular complications such as retinal hemorrhage, retinal detachment, optic atrophy, retinal ischemia or infarction, cataracts, corneal opacity, or severe intraocular inflammation were absent in both groups.

Pharmacokinetic Analysis. The mean concentration-time profiles of groups I and II in the vitreous humor are shown in Figure 1. Relevant pharmacokinetic parameters are listed in the Table. As shown in Figure 1, nonlinear decay in the log concentration profiles of PVI was observed during the initial 2 hours. In the noncompartmental analysis, the dose increase from 0.1% to 0.3% resulted in an overproportional increase of AUC; the dose-normalized AUC values of groups I and II were 0.222 and 0.478 h/mL, respectively. Moreover, CL and V_{ss} tended to decrease as the dose increased (Table). These results indicated that vitreous PVI exhibited dose-dependent (nonlinear) pharmacokinetics after ocular injection. Thus, nonlinear Michaelis-Menten kinetics were used to describe the elimination process in the compartmental analysis. The $t_{1/2}$ values of the 0.1% and 0.3% PVI in the vitreous were 3.27 and 3.58 hours, respectively. The PVI concentration data was well described by the one-compartment model with single Michaelis-Menten elimination kinetics, and the V_d , V_{max} , and K_m values were successfully estimated.

Electroretinography. Before and after PVI injection, there were no significant changes in the mean values of a- and b-wave amplitudes at baseline, 6, and 12 hours in groups I and II. Histologic Examination. No retinal damage was noted in either group.

After PVI injection, all four groups demonstrated improvement of conjunctival hyperemia, chemosis, and vitreous inflammation, compared to control eyes. Of 10 eyes, 8 eyes in groups A and B had moderate vitreous opacity. Mild vitreous opacity was observed in all eyes of groups C and D. Control eyes showed manifestations of severe bacterial endophthalmitis including chemosis and severe vitreous opacity at day 14. Of 10 eyes, 4 eyes (receiving 20, 60, 60, and 70 CFU) and 3 eyes (receiving 20, 40, and 60 CFU) demonstrated *S. epidermidis* growth in vitreous samples in groups A and B at day 14, respectively. However, there was no bacterial growth in groups C and D. The control group had bacterial growth of 5,500 to 550 CFU (average) in all eyes. Based on previous results, we selected 0.1% and 0.3% concentrations of PVI for evaluation in this study. Electroretinographs and histologic examination of the retina confirmed that both 0.1% and 0.3% PVI were tolerable in the phase I. There's no serious adverse events or side effects were reported from any study site.

Discussion

Intravitreal use of PVI was first reported by Whitacre and Crockett.⁴ In their study, PVI at concentrations of 0.05 to 0.5% did not produce any notable retinal damage, although one eye had

mild vitritis after 0.5% PVI injection.^{5,6} However, 5.0% PVI induced severe retinal damage in all eyes.^{7,8,9} They concluded that PVI concentrations between 0.05% and 0.5% would be tolerable in the eyes confirmed a safety threshold of up to 0.4% PVI.^{10,12,13} Additionally, they identified the ineffectiveness of a single 0.1% PVI injection for *S. epidermidis*¹⁰ and concluded that intraocular PVI was not a useful treatment for bacterial endophthalmitis. However, this result could mostly be attributable to the single injection as well as low concentration (0.1%). This hypothesis was supported by the work of Brozou et al.,¹¹ who showed that *S. epidermidis* improved after a 0.2% PVI injection.

In cases of endophthalmitis, the standard care is intravitreal drug administration with or without surgical treatment.¹⁶ Repeated injections of antibiotics are occasionally administered in cases that do not fully recover after a single injection of the drug. In such cases, efficacy and safety have been proven in previous studies.^{17,18} Thus far, the half-life of various antimicrobial and antifungal agents have been reported to be from to 30 hours.¹⁹ The present study showed that single use of 0.1% PVI did not have any beneficial effect on endophthalmitis nor keratitis which correlates with the results of previous studies, whereas repeated injections of 0.1% PVI were found to be effective. Moreover, repeated injections achieved better results in the vitreous culture for bacterial growth, ERG, and histology than a single PVI injection with high concentration (0.3%). Both repeated injection of 0.1% and 0.3% PVI did not differ in the treatment of endophthalmitis and keratitis. Our results demonstrated that PVI could have a beneficial effect in treating bacterial infection by using repeated injections regard of its 3-hour half-life, even at a low concentration. Moreover, it is well known that PVI has an additional advantage as a broad-spectrum agent against microorganisms, compared to antibiotics.

There are some limitations to this study. First, it is based on an animal model and the study was designed to investigate short-term changes. Response to intraocular infections and subsequent treatment in rabbits may differ from that in humans. Thus, our results from this experimental animal model may not reflect the clinical course in humans directly. Second, this study could lack sufficient power to detect the beneficial effects of PVI on bacterial counts in the vitreous due to the small number of animals used. A larger number of animals tested could generate a different outcome. Finally, it is most likely that similar results would not be observed if we altered the types of bacteria, size of the inoculation, and timing of the treatment.

Conclusion

In conclusion, PVI has a 3-hour half-life in the vitreous. Both 0.1% and 0.3% PVI can be tolerated in rabbit eyes. Repeat injections of intravitreal PVI could be effective for the treatment of bacterial infection, even at a low concentration. Further investigation of intraocular PVI use should be conducted for the treatment of various pathogens causing infectious illness. We found that povidone-iodine is effective for treatment of infectious keratitis caused by a broad range of bacteria. Use of povidone-iodine may reduce the incidence of vision loss caused by corneal scarring, which is a particularly the important problem.

References

1. Hanscom TA. Postoperative endophthalmitis. *Clin Infect Dis*. 2004; 38: 542–546.
2. Weber DJ, Hoffman KL, Thoft RA, Baker AS. Endophthalmitis following intraocular lens implantation: report of 30 cases and review of the literature. *Rev Infect Dis*. 1986; 8: 12–20.
3. Ng EW, Samiy N, Ruoff KL, et al. Treatment of experimental *Staphylococcus epidermidis* endophthalmitis with oral trovafloxacin. *Am J Ophthalmol*. 1998; 126: 278–287.
4. Reimer K, Wichelhaus TA, Schäfer V, et al. Antimicrobial effectiveness of povidone-iodine and consequences for new application areas. *Dermatology*. 2002; 204(1): 114–120.
5. Kawana R, Kitamura T, Nakagomi O, et al. Inactivation of human viruses by povidone-iodine in comparison with other antiseptics. *Dermatology*. 1997; 195(2): 29–35.
6. Isenberg SJ, Apt L, Valenton M, et al. A controlled trial of povidone-iodine to treat infectious conjunctivitis in children. *Am J Ophthalmol*. 2002; 134: 681–688.
7. Isenberg SJ, Apt L, Yoshimori R, et al. Efficacy of topical povidone-iodine during the first week after ophthalmic surgery. *Am J Ophthalmol*. 1997; 124: 31–35.
8. Apt L, Isenberg SJ, Yoshimori R, et al. The effect of povidone-iodine solution applied at the conclusion of ophthalmic surgery. *Am J Ophthalmol*. 1995; 119: 701–705.
9. Whitacre MM, Crockett RS. Tolerance of intravitreal povidone-iodine in rabbit eyes. *Curr Eye Res*. 1990; 9: 725–732.
10. Guigou S, Pommier S, Meyer F, et al. Efficacy and safety of intravitreal dexamethasone implant in patients with diabetic macular edema. *Ophthalmologica*. 2015; 233: 169–175.
11. Forster RK. The endophthalmitis vitrectomy study. *Arch Ophthalmol*. 1995; 113: 1555–1557.

12. Shaarawy A, Grand MG, Meredith TA, Ibanez HE. Persistent endophthalmitis after intravitreal antimicrobial therapy. *Ophthalmology*. 1995; 102: 382–387.
13. Minogue MJ, Playfair TJ, Gregory-Roberts JC, Robinson LP. Cure of Paecilomyces endophthalmitis with multiple intravitreal injections of amphotericin B. Case report. *Arch Ophthalmol*. 1989; 107: 1281.
14. Peyman GA, Lad EM, Moshfeghi DM. Intravitreal injection of therapeutic agents. *Retina*. 2009; 29: 875–912.
15. Houang ET, Gilmore OJ, Reid C, Shaw EJ. Absence of bacterial resistance to povidone iodine. *J Clin Pathol* 1976; 29(8): 752–755.
16. Apt L, Isenberg SJ, Yoshimori R, Spierer A. Outpatient topical use of povidone-iodine in preparing the eye for surgery. *Ophthalmology* 1989; 96(3): 289–292.
17. Isenberg SJ, Apt L, Yoshimori R, Pham C, Lam NK. Efficacy of topical povidone-iodine during the first week after ophthalmic surgery. *Am J Ophthalmol* 1997; 124(1): 31–35.